











Determinants and Biomarkers of Progression Independent of Relapses in Multiple Sclerosis

Massimiliano Calabrese ¹, Paolo Preziosa ^{2,3,4*}, Antonio Scalfari ^{5*}, Elisa Colato,^{1*} Damiano Marastoni,^{1*} Martina Absinta,⁶ Marco Battaglini,^{7,8} Nicola De Stefano,⁸ Massimiliano Di Filippo ⁹, Simon Hametner,¹⁰ Owain W. Howell ¹¹, Matilde Inglese,¹² Hans Lassmann,¹³ Roland Martin,^{14,15,16} Richard Nicholas ¹⁷, Richard Reynolds,¹⁸ Maria A. Rocca ^{2,3,4}, Agnese Tamanti,¹ Marco Vercellino,¹⁹ Luisa Maria Villar ²⁰, Massimo Filippi ^{2,3,4,21,22} and Roberta Magliozzi ¹

Clinical, pathological, and imaging evidence in multiple sclerosis (MS) suggests that a smoldering inflammatory activity is present from the earliest stages of the disease and underlies the progression of disability, which proceeds relentlessly and independently of clinical and radiological relapses (PIRA). The complex system of pathological events driving “chronic” worsening is likely linked with the early accumulation of compartmentalized inflammation within the central nervous system as well as insufficient repair phenomena and mitochondrial failure. These mechanisms are partially lesion-independent and differ from those causing clinical relapses and the formation of new focal demyelinating lesions; they lead to neuroaxonal dysfunction and death, myelin loss, glia alterations, and finally, a neuronal network dysfunction outweighing central nervous system (CNS) compensatory mechanisms. This review aims to provide an overview of the state of the art of neuropathological, immunological, and imaging knowledge about the mechanisms underlying the smoldering disease activity, focusing on possible early biomarkers and their translation into clinical practice.

ANN NEUROL 2024;00:1–20

View this article online at [wileyonlinelibrary.com](https://onlinelibrary.wiley.com/doi/10.1002/ana.26913). DOI: 10.1002/ana.26913

Received Oct 9, 2023, and in revised form Jan 4, 2024. Accepted for publication Feb 15, 2024.

Address correspondence to Prof. Massimiliano Calabrese, Azienda Ospedaliera Universitaria Integrata di Verona, P.le Ludovico Alberto Scuro 10, 37135, Verona, Italy. E-mail: massimiliano.calabrese@univr.it

*These authors equally contributed to the paper.

From the ¹Department of Neurosciences and Biomedicine and Movement, The Multiple Sclerosis Center of University Hospital of Verona, Verona, Italy; ²Neuroimaging Research Unit, Division of Neuroscience, IRCCS San Raffaele Scientific Institute, Milan, Italy; ³Neurology Unit, IRCCS San Raffaele Scientific Institute, Milan, Italy; ⁴Vita-Salute San Raffaele University, Milan, Italy; ⁵Centre of Neuroscience, Department of Medicine, Imperial College, London, UK; ⁶Translational Neuropathology Unit, IRCCS San Raffaele Scientific Institute, Milan, Italy; ⁷Siena Imaging S.r.l., Siena, Italy; ⁸Department of Medicine, Surgery and Neuroscience, University of Siena, Siena, Italy; ⁹Section of Neurology, Department of Medicine and Surgery, University of Perugia, Perugia, Italy; ¹⁰Division of Neuropathology and Neurochemistry, Department of Neurology, Medical University of Vienna, Vienna, Austria; ¹¹Institute of Life Sciences, Swansea University Medical School, Swansea, UK; ¹²Dipartimento di neuroscienze, riabilitazione, oftalmologia, genetica e scienze materno-infantili – DINOGMI, University of Genova, Genoa, Italy; ¹³Center for Brain Research, Medical University of Vienna, Vienna, Austria; ¹⁴Institute of Experimental Immunology, University of Zurich, Zurich, Switzerland; ¹⁵Therapeutic Design Unit, Center for Molecular Medicine, Department of Clinical Neurosciences, Karolinska Institutet, Stockholm, Sweden; ¹⁶Cellerys AG, Schlieren, Switzerland; ¹⁷Department of Brain Sciences, Faculty of Medicine, Burlington Danes, Imperial College London, London, UK; ¹⁸Division of Neuroscience, Department of Brain Sciences, Imperial College London, London, UK; ¹⁹Multiple Sclerosis Center & Neurologia I U, Department of Neuroscience, University Hospital AOU Città della Salute e della Scienza di Torino, Turin, Italy; ²⁰Department of Immunology, Ramon y Cajal University Hospital. IRYCIS. REI, Madrid, Spain; ²¹Neurorehabilitation Unit, IRCCS San Raffaele Scientific Institute, Milan, Italy; and ²²Neurophysiology Service, IRCCS San Raffaele Scientific Institute, Milan, Italy

The Rationale of the Review

The heterogeneous and largely unpredictable clinical outcome of multiple sclerosis (MS) has puzzled physicians for decades. Most patients (~85%) present with a relapsing–remitting (RR) course, characterized by acute attacks followed by complete or partial recovery, and eventually experience progressive accumulation of irreversible disability¹ in the later stage of the disease (secondary progressive [SP] MS). While this phenotypic distinction enhances homogeneity in clinical trials and allows standardized communication among clinicians, emerging evidence suggests a biological continuum in which pathological mechanisms underlying relapses and progression coexist from the early stage of the disease.^{2–5} Despite the successful therapeutic suppression of relapses and magnetic resonance imaging (MRI) active inflammatory lesions (Fig 2A–D), MS patients often report a gradual but progressive worsening of physical and cognitive functions. This discrepancy indicates an ongoing “smoldering” biological activity, albeit challenging to detect, which is commonly referred to as progression independent of relapsing activity (PIRA)² or silent progression,⁶ and is distinct from relapse-associated worsening (RAW).

In the pooled analysis of the OPERA trials, in both the ocrelizumab and interferon-treated groups, PIRA events accounted for disability accumulation in a substantial proportion (>80%) of RRMS patients despite their relatively short disease duration (mean six years).² A large pooled clinical trials dataset³ and recent data from a real-world observational cohort⁵ confirmed this finding. Among patients from the Italian MS registry experiencing disease worsening, PIRA was more commonly reported than RAW since the second year after the disease onset. Furthermore, its frequency proportionally increased with the disease duration.⁵ Notably, patients free of ongoing inflammatory attacks can also experience significant deterioration of their cognitive function from the earliest disease stages,^{7,8} which accumulates silently for several years.⁹ However, PIRA has historically referred to progression independent of clinical relapses but inadequately captures subclinical disease activity accounting for disease worsening. Indeed, the emerging definition of PIRA includes new asymptomatic brain and spinal cord lesions PIRMA (progression independent of relapse and MRI activity), thus aligning to outcomes measures used in MRI research and trials.

The effective suppression of acute inflammatory parameters (relapses and active MRI lesions) might falsely indicate disease control while underlying biological mechanisms leading to a subtle deterioration remain clinically undetected. Understanding mechanisms and identifying biomarkers of such silent deterioration remain essential unmet needs.

Pathological Substrates

Immunopathologically, it is plausible to hypothesize that the smoldering MS activity is characterized by a continuous interplay between intrathecal (cerebrospinal fluid [CSF] and meninges) and parenchymal chronic processes of inflammation and neurodegeneration, which associate glial activation and neuro-axonal dysfunction/loss with additional age-related pathological mechanisms.^{10–14}

A complex interaction among different immunopathogenic and neurodegenerative processes (Fig 1) possibly underlines the disease progression and includes: (1) acute blood-brain barrier breakdown/brain and spinal cord atrophy; (2) perivascular/meningeal inflammation; (3) acute focal white matter (WM) lesions/ diffuse gray matter (GM) lesions; (4) acute glia priming/chronic microglia activation; (5) mitochondrial damage/impaired energy production; (6) loss of trophic support/ remyelination failure.

Several potential underlying mechanisms for PIRA¹⁵ have been suggested in the past decade including the formation of meningeal lymphoid-aggregates with the associated subpial cortical demyelination and the consequent accumulation of neuronal damage and cortical atrophy, the accumulation of chronic active lesions (CAL, also termed slowly expanding, smoldering or mixed active/inactive lesions); and the remyelination failure. However, their exact extent, involvement, timing, and role still need to be fully understood. Possible concomitant key drivers of PIRA could also be (1) the slowly accumulating WM and GM demyelination, possibly linked to the presence of perivascular, meningeal, and choroid plexus inflammatory cell infiltrates; (2) persistent microglial activation (driven by degenerating cells and inflammation) contributing to neuro-axonal energy failure through oxidative stress mechanisms; and (3) ongoing retrograde and anterograde axonal injury.

Previous histological and more recent combined imaging-neuropathological studies highlighted heterogeneous immunopathological patterns of active demyelination among patients, although lesions' homogeneity may also occur within individual patients,^{16–18} possibly converging into a final common pathway related to chronic neuronal-axonal damage and disease progression.

Chronic Active Lesions and Iron-Related Changes

Pathologically, CAL are characterized by a rim of activated myeloid phagocytes (microglia and macrophages) with occasional myelin degradation products as a sign of continuous low-level myelin destruction. These lesions differ from chronic inactive lesions in the number of myeloid phagocytes at their rims but a similar number of CD3+ T cells, which remain very sparse, suggesting a

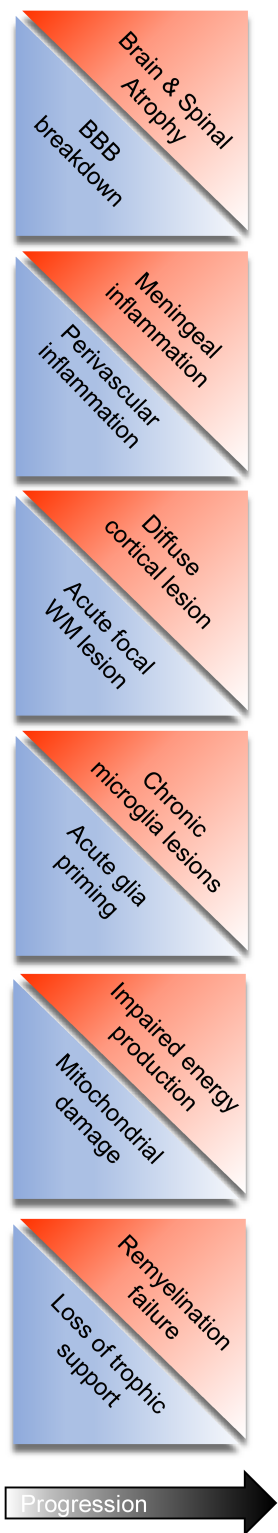


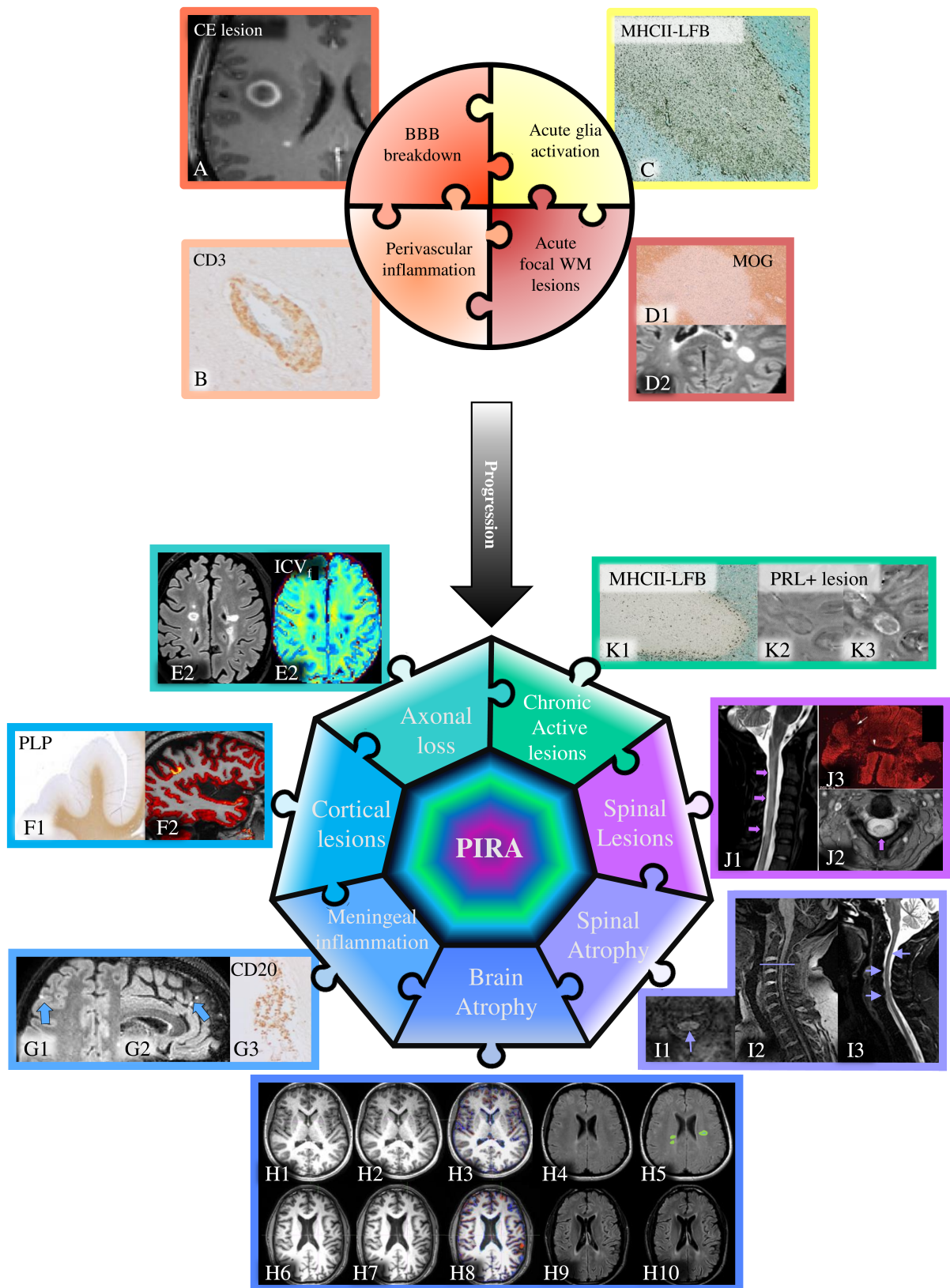
Figure 1: Diagram representing different parameters and features that may change during disease progression and contribute to progression independent of relapse: (A) acute blood-brain barrier breakdown/brain and spinal cord atrophy; (B) perivascular/meningeal inflammation; (C) acute focal white matter (WM) lesions/ diffuse gray matter (GM) lesions; (D) acute glia priming/chronic microglia activation; (E) mitochondrial damage/impaired energy production; (F) loss of trophic support/ remyelination failure.

crucial role of microglia and macrophages in progressive lesion activity.¹⁹ In ~45% of pathologically detected CAL, phagocytes accumulate iron and frequently adopt a senescent morphology (Fig 2K1).^{20–22} The myeloid cells at the rim have an activated phenotype with expression of proinflammatory p22phox, CD40, CD86, and inducible nitric oxide synthase (iNOS), C1QA, as well as a lack of anti-inflammatory CD206 expression and loss of the quiescence marker P2ry12.^{20,23–25} Conversely, the putatively anti-inflammatory marker CD163 is expressed on the myeloid cells rims.^{24–27} In line with the pro-inflammatory activation, an increased number of APP+ axonal spheroids is found at the slowly expanding rims,^{28–30} which indicates axonal degeneration, as confirmed by elevated neurofilament light chain serum levels found among patients with a large number of MRI-detected iron rim lesions.^{30,31} The microglia and macrophages at the iron rims additionally express the activation marker translocator protein (TSPO), which can be detected by positron emission tomography (PET) imaging using a TSPO-specific tracer in-vivo.³² In addition to contributing to the axonal destruction, the inflammatory environment at the slowly expanding rim, including secreted mediators from T cells, particularly IFN γ ,³³ appears responsible for the remyelination failure in this type of lesion.^{20,26} Notably, the proportion of slowly expanding but not classically active lesions strongly correlated with disease severity in a large study on 182 autopsy MS cases.³⁴

Grey Matter Demyelination and Meningeal Inflammation (Including Spinal Cord and Deep grey matter)

CAL are also seen in the cortical GM, deep GM, and the spinal cord.³⁵ These can be more extensive than WM lesions and frequently appear to follow an outside-in gradient, typified by the subpial lesions of the neocortical GM (Fig 1F1,F2).^{36,37} While most GM lesions in the cerebral cortex follow a subpial pattern (so-called type III), intracortical perivascular lesions (type II) and lesions that extend into both the GM and WM (leukocortical type I) are also frequently observed, although in smaller numbers than subpial lesions.^{38–40} Unlike WM lesions, minimal parenchymal or perivascular immune cell infiltration is associated with most cortical GM lesions,^{38,39} leading to the view that they are unlikely to be linked to acute inflammatory events. Significant GM demyelination can also be seen in deeper GM regions, including the thalamus^{41,42} and cerebellum.^{43,44} In the spinal cord, the extent of demyelination in the GM is generally more severe than that observed in the WM.⁴⁵

In contrast to the lack of association between GM parenchymal and perivascular infiltrates and GM demyelination,



(Figure legend continues on next page.)

there is a significant relationship between demyelination and the degree of immune cell infiltration in the overlying meninges (Fig 2F1,F2,G1,G2).^{10,40,46–49} The presence of large immune cell aggregates of both T and B cells, together with the development of tertiary lymphoid structures in some cases,^{40,48} is suggested to give rise to an inflammatory and cytotoxic CSF that can both chronically activate cells within the CNS parenchyma and also provide cytotoxic mediators that can diffuse into the underlying tissues.^{50,51} The degree of immune cell infiltration in the meninges is also associated with increased WM lesion number and activity, particularly in the spinal cord,^{45,52} but also in the subcortical WM,⁵³ suggesting a similar mechanism of compartmentalized inflammation-induced pathology in both the WM and GM. Thus, there is substantial evidence for a progressive but slow accumulation of demyelinating and neurodegenerative pathology that is not related to clinical inflammatory relapses and may drive the accumulating disability throughout the disease course of MS.

Focus on Surface-in Gradient of Neuro-glia Abnormalities. In progressive MS, the meningeal inflammation is associated with a substantial “surface-in” gradient of neuronal and axonal loss in subpial cortical GM lesions⁵⁴ and subependymal thalamic lesions.⁴¹ Even in the absence of demyelination, a substantial graded neuroaxonal damage can be observed, albeit always associated with a concomitant gradient of astrocyte and oligodendrocyte loss, microglia activation, high levels of meningeal inflammation, and with faster and more severe disease progression.^{37,41,54,55} Similarly, the surface-in gradient of

MS thalamic damage is correlated to a specific CSF protein profile, including (1) a high level of neurodegeneration markers, such as neurofilaments light chain (NFL); (2) molecules related to both innate immune activity and lymphoid neogenesis (CCL19, CXCL10, CXCL13); and (3) major inflammatory factors (including sTNFR1, fibrinogen, IFN- γ , IL2 and IL10). These data strongly suggest a key role of intrathecal inflammation in the slow build-up of diffuse GM pathology and support the use of CSF profile as a biomarker signature of progressive GM pathology. A similar gradient of brain abnormalities is found at early disease phases, even in pediatric MS.^{37,56–58} In addition, these data suggest a link between inflammatory/cytotoxic CSF and accumulating neuronal loss, also reproduced in animal models in which the levels of neurotoxic pro-inflammatory cytokines, such as TNF and lymphotoxin-alpha, are chronically elevated in the meningeal space.^{37,41,51,55,59}

Neuronal and Synaptic Damage in the Cortex and Deep Grey Matter

Neuroaxonal loss, rather than demyelination, is likely to be one of the main determinants of GM atrophy,^{60–62} and is strongly associated with disability progression. The neuroaxonal loss has been described to a variable extent in all GM structures, including the cerebral cortex (19%–40%),^{54,60,63–67} cerebellar cortex (29%),⁴³ hippocampus (27%),⁶⁸ thalamus (30%–35%),^{69,70} and spinal cord (36–75%).^{71–74} Neuroaxonal loss is probably related to lesion-dependent and lesion-independent mechanisms. Indeed, retrograde neuronal degeneration can occur because of focal WM damage.⁴⁶ In the GM, reduced

Figure 2: Diagram representing the parameters and features that may contribute to the different MS phases and progression independent of relapse: (A) Contrast enhancing lesion with blood–brain barrier (BBB) breakdown; (B) CD3+ T cell infiltrating perivascular space; (C) active multiple sclerosis (MS) lesions characterized by elevated presence of MHC class II+ activated microglia/macrophages; (D) focal white matter lesions detected neuropathologically by myelin oligodendrocyte glycoprotein immunostaining (D1) and using fluid attenuated inversion recovery (FLAIR) MRI images (D2); (E) T2 hyperintense white matter lesions visible on T2-FLAIR sequence (E1) characterized by a lower intracellular volume fraction (ICV_f), E2, (derived from neurite orientation dispersion and density imaging, NODDI, and representing the space bounded within membranes processes typically considered a measure of axons and dendrites contribution) compared to normal appearing white matter suggesting substantial intralésional axonal loss; (F) cortical lesions visible as extensive areas of demyelination by using myelin proteolipid protein (PLP) immunostaining (F1) or appearing as hyperintensities in double inversion recovery sequences overlaid to the structural T1w sequence (F2) to assess the extension in the cortex; (G) meningeal inflammation as represented by leptomenigeal enhancement in post-gadolinium FLAIR acquisitions (G1-G2) and meningeal infiltrate enriched in CD3+ T cells (G3); (H) brain volume loss independent of disease activity with images referring to 2 patients (subject 1 images H1 to H5; subject 2 images from H6 to H10) with the same atrophy rates over 2 years (~ -1.1% per year) and different focal activity, H1/H6 T1w at baseline, H2/H7 T1w after 24 months, H3/H4 regions where edge displacement is most evident as measured by the SIENA method, H4/H9 shows the relative FLAIR images at baseline and H5/H10 at M24 where the first subject is active (green border/light blue body indicating new lesions) the second shows no changes in lesion load over the 2 years; (I) spinal cord progressive damage as represented in an axial (I1) and sagittal (I2) 3 T 3D MP2RAGE and in a 3 T 3D STIR (I3) [courtesy of Dr. Daniel Reich NINDS, NIH]; (J) diffuse spinal cord lesions as represented in a sagittal STIR (J1), axial multi-echo GRE (J2) and myelin oligodendrocyte glycoprotein immunostaining (J3) [Reali et al., J Neuropath 2020]; (K) chronic active lesion characterized by MHCII+ activated microglia accumulation at the lesion edge of luxol fast blue stained white matter (WM) lesion (K1) and paramagnetic rim lesions detected using MRI filtered phase (K2) and Quantitative Susceptibility Mapping (K3).

neuronal density has often been more pronounced in cortical lesions, particularly those close to pia/CSF boundaries,^{43,63,64,70,73} indicating a causal relationship between GM demyelination and neuronal loss. In addition, specific neuronal subpopulations may be more susceptible to MS-related damage. Recent studies have suggested a selective vulnerability of inhibitory neuronal networks with a preferential loss of inhibitory interneurons in the MS cortex, potentially altering normal brain network functioning.⁷⁵

Similarly, the diffuse synaptic loss observed in MS brains is probably related to lesion-dependent and lesion-independent mechanisms. Data from animal models and post-mortem MS brains suggest that acute synaptic loss is associated with inflammation, which resolves and is followed by synaptic re-organization.^{76–83} Synapses are probably targeted by complement factors C1q and C3 and removed by activated microglia in close contact with neurons.^{77,81–85} In animal models, inflammatory cytokines (such as TNF α , IL-1, IFN γ) have been shown to induce synaptic alterations^{79,80,86} and could contribute to synaptopathy among MS patients. Beyond structural synaptic damage, inflammation in the CNS can lead to abnormalities in the ability of synapses to express forms of long-term plasticity, such as long-term potentiation, contributing to brain network failure and disconnection.

Lower synaptic density has been reported in GM lesions compared to the normal-appearing GM (NAGM),^{64,74,76,87} suggesting that focal demyelination enhances long-term synaptic loss. However, the synaptic loss appears to be relatively independent of focal demyelination^{76,77,88} and was found to be unrelated to the extent of the neuroaxonal loss,^{76,77,88} suggesting the coexistence of a diffuse primary synaptic pathology, possibly driven by the chronic inflammation present in the GM and meninges.

Role of Chronic Oxidative Injury/Mitochondrial Damage and Energy Deficit

The occurrence of an “energetic crisis” is widely recognized as one of the key pathological mechanisms underlying the dysfunction of the neuro-axonal unit.⁸⁹ Demyelinated axons require more energy to operate and guarantee conduction, ultimately increasing the metabolic demand.⁹⁰ During demyelination, the mitochondria within the MS plaques move from the neuronal cell body to the axon, increasing the axonal mitochondrial content.⁹¹ Such a homeostatic response cannot fully and persistently compensate for the increased axonal energy demand. Nuclear-encoded mitochondrial genes and the functional activities of mitochondrial respiratory chain complexes I and III, are decreased in the motor cortex of

severely disabled MS patients,⁹² and multiple deletions of mitochondrial DNA (mtDNA) have been histologically demonstrated throughout the GM in progressive MS, with respiratory-deficient neurons harboring high levels of clonally expanded mtDNA deletions at the single-cell level.⁹³ In demyelinated axons predominantly located at the edge of chronic active lesions, reduced levels of complex IV activity have been shown,⁹⁴ together with an inverse correlation between complex IV activity and macrophage/microglial density, suggesting that soluble products released by such cells might be responsible for the observed functional impairment.^{94,95} Reactive oxygen and nitrogen species (ROS and RNS) deriving from innate immune cells, when excessively liberated, can trigger mitochondrial pathology and initiate a process of focal axonal swelling, determining axon fragmentation.⁹⁶ Further experimental evidence of the contribution of mitochondrial and energy deficits comes from fluid biomarker studies. Patients with progressive MS display increased CSF levels of mtDNA,⁹⁷ while CSF lactate levels correlate with disease-worsening and axonal damage markers, such as neurofilament light protein.⁹⁸ It is worth noting that not only a condition of “virtual” hypoxia due to an increased energy demand but also the presence of “true” tissue hypoxia (i.e., oxygen deficiency) has been hypothesized to occur in MS.⁸⁹ Taken together, evidence suggests the vicious “hypoxia-inflammation” cycle as a potential target⁹⁹ for neuroprotective strategies aiming at restoring the neuronal mitochondrial activity and ultimately preventing the disease progression.¹⁰⁰

Alterations in Normal Appearing White and Grey Matter

The normal-appearing tissue of the WM (NAWM) and GM is affected by axonal injury (both intrinsic and extrinsic to the tissues), gliosis, widespread diffuse microglial activation, and disrupted myelin, which displays altered biochemical and biophysical qualities.^{101–105} Normal composition of mature myelin is essential for oligodendrocyte and axonal health, myelin ensheathment, and placement and organization of the nodes of Ranvier.¹⁰⁶ Widespread changes at the node of Ranvier, the flanking paranodal assembly, and the juxtaparanode, are seen near and far from the MS lesion.^{107–109} Notably, activated microglia are associated with nodal disruption, where attenuating microglial activation with minocycline reduces nodal and paranodal damage and blocking glutamate, which is excessively generated by activated microglia, abrogates this change.^{107–109} These changes in the NAWM and NAGM could contribute to clinical worsening independent of new inflammatory attacks.^{90,96}

Immuno-pathological Mechanisms

Role of Adaptive Immunity

Focus on the Role of T Cells. Organ-specific adaptive immune mechanisms against several target antigens in the periphery, CSF, and focal lesions are involved in MS pathogenesis. It is currently assumed that the pathological immunological processes start in the periphery and become chronic in the CNS compartment (outside-in hypothesis).¹¹⁰ Key players of the antigen-specific immune response are autoreactive CD4+ T cells,¹¹⁰ but also proinflammatory B cells at various differentiation stages¹¹¹ (for a detailed review, see^{112,113} and below).

The MS-associated HLA-DR15 molecules shape a CD4+ T cell repertoire that is fully functional and protective against infections but also carries T cell receptors with cross-reactivity against CNS antigens, including myelin basic protein, proteolipid protein, myelin oligodendrocyte glycoprotein (MOG),^{114,115} Ras guanyl-releasing protein 2 (RASGRP2),¹¹⁶ GDP L-fucose synthase,¹¹⁷ Prokineticin-2, reticulon-3, fatty acid binding protein 7 (FABB7), synaptosomal-associated protein 91,¹¹⁸ and alpha-crystallin B (CRYAB).¹¹⁹ The majority of autoreactive CD4+ T cells in the peripheral blood and CSF are proinflammatory, expressing a T helper (Th) 1 (secreting IFN-) or Th17 (secreting IL-17) or Th1* (secreting both) phenotype.^{116,120–122}

Other Th cell subtypes, such as T follicular helper cells¹²³ and Th2 cells secreting IL-4 and IL-5, have also been identified.¹²⁴ Th1 and Th1* CD4+ T cells appear most important and engage in crosstalk and immunological synapse formation with proinflammatory B cells, which results in increased spontaneous or autoproliiferation and enrichment for brain-homing T cells.¹¹⁶ These T cells recognize HLA-DR15-derived self-peptides, which may play a role during thymic selection and are also presented on peripheral memory B cells,¹²⁵ but also foreign antigens from the MS-associated EBV and gut microbiota like *Akkermansia muciniphila*.^{117,125} Interestingly, 1 of the abovementioned MS target antigens, RASGRP2, is expressed by the brain's proinflammatory B cells and cortical neurons.¹¹⁶ Increasing evidence from the peripheral blood, the CSF, and meningeal follicles hints at a role of the cross-talk between proinflammatory memory B cells and plasmablasts on 1 side and memory CD4+ T cells with a Th1/Th1* phenotype on the other.^{116,126} The chemokine receptor CXCR3 on B and Th1 T cells,¹²⁷ its ligands CXCL9, CXCL10, and CXCL13, IFN-gamma and nuclear factor kappa B signalling¹²⁸ are all involved in this interaction. CSF-infiltrating T cells may respond to a multiple of the abovementioned MS autoantigens, but also viral epitopes from EBV¹²⁹ and Torque Teno Virus (TTV),¹³⁰ and even HLA-DR15¹²⁵ and immunoglobulin-derived peptides.¹³⁰

A role of adaptive (T cell-mediated) immune mechanisms in PIRA is indicated by T cell receptor sequencing studies that have shown clonal CD4+ and CD8+ T cell expansions in chronic active lesions¹³¹ and demonstration that a clonally expanded RASGRP2-specific CD4+ T cell clone has also been found in the autoproliiferating T cell compartment in the periphery.¹¹⁶ A contribution to chronic active lesions and PIRA is further supported by a single-cell RNA sequencing study, which showed that lymphocyte activation and proinflammatory markers contribute to their immune signature.²³ Finally, a correlation exists between lymphocyte infiltrates in the meninges and WM lesions in progressive MS.⁵³ While proving the relevance of adaptive immune mechanisms for PIRA is challenging, the above observations indicate that they might be involved.

Focus on the Role of B Cells. The clinical efficacy of B cell depletion strategies in preventing new lesion formation^{130,132} confirmed the central role of B cells in MS pathogenesis. Several pieces of evidence underscore the close interaction between T and B cells crosstalk and the importance of related cytokine pathways in the periphery and intrathecally in the CSF/meninges. Among these pathways, the expression of chemokine receptors CXCR3 and T-bet by CD4+ Th1 cells and B cells^{126,133,134}, the demonstration of their ligands (CXCL10 and CXCL13) and of other cytokines (LT, TNF, IFN γ)^{59,135,136} were largely investigated in the past decade.

B cells are mainly seen in the subarachnoid spaces in meningeal tertiary lymphoid-like structures.^{10,40,48} They can also be found in the perivascular space of medium-sized veins within the plaque centre, mainly in the WM and, to a lesser extent, in the GM.^{137,138} In these intracerebral niches, B cells may contribute to compartmentalized inflammation by perpetuating humoral immune response, antigen presentation, and release of proinflammatory and cytotoxic mediators.^{139,140} Supernatants from cultured B cells from MS patients were toxic and induced more significant apoptosis in cultured neurons and oligodendrocytes than supernatants from cultured B cells from healthy controls.^{139,140} The same antigen-experienced B cell clones were found in meningeal immune cell infiltrates, the CSF and perivascular parenchymal lesions.^{141–143} In addition, it has been demonstrated that B cell clones are bidirectionally exchanged between the CNS and the periphery and that affinity maturation occurs on both sides of the blood–brain barrier.¹⁴⁴ More recently, a study in mouse models suggested that meningeal B cells encompass multiple stages of development and may originate in calvaria and then infiltrate and mature in the meninges via a network of channels uncoupled from the systemic circulation.¹⁴⁵

Genetic variation in B cell activation¹⁴⁶ as well as the infection by lymphotropic viruses, such as the Epstein–Barr virus,^{147,148} represent the prevalent hypothesis of aberrant and altered intrathecal B cell survival and activity in MS. All these findings suggest that the same stimuli might be involved in both initial B cell activation and clonal expansion events and then in the chronic invasion of different niches of the CNS.¹¹²

Role of Innate Immunity

Focus on Microglia. Many pro-inflammatory mechanisms have been suggested to be involved in active demyelination and neurodegeneration. Still, the production of reactive oxygen species appears particularly important. In contrast to rodent models, NADPH oxidase (Nox2) expression in human microglia and macrophages is prominent, while the iNOS expression is sparse. This is associated with a profound acute oxidative injury in neurons and glia in active lesions.¹⁴⁹ In the earliest descriptions of MS pathology in the late 19th century, it was already noted that active demyelination and neurodegeneration in MS lesions are closely associated with activated microglia and macrophages. A subset of microglia and macrophages at the edge of chronic active lesions contain iron and can be visualized in vivo with MRI.²⁰ Such an iron rim is a marker for the slow expansion of lesions, relevant for silent or overt disease progression in MS.²⁸

New markers became available during the past few years, allowing us to differentiate between activated microglia and recruited myeloid cells within the lesions. They suggest most phagocytes in active MS lesions are derived from the microglia pool.²⁴

Recent spatial transcriptomics or proteomics studies confirmed the findings, which had been elucidated before with conventional methodology.^{23,150,151} They provide evidence of a profound heterogeneity of microglia and macrophage phenotypes, with different compositions in lesions based on variable contributions of active demyelination, inactive lesions or remyelination. Whether these different cell phenotypes reflect genuine cellular subpopulations or the transition between naïve, pro-inflammatory and anti-inflammatory cells is a question that remains unresolved. Meningeal inflammation in progressive MS patients was recently found to induce phenotypic changes in cortical microglia that are differentially associated with neurodegeneration.⁸²

Focus on the Role of Complement. Complement is a key component of the innate immune system. The microglia synthesize, activate, and respond rapidly to soluble and membrane-bound products of complement activation.¹⁵¹ Genetic variants in the complement genes are associated

with a more severe clinical outcome,^{23,152,153} and increased complement activation is reported in cohorts that experienced a worsening progressive MS course.^{42,84,154,155} Complement expression is induced in cortical glia in a chronic leptomeningeal inflammation model. Complement contributes to compartmentalized inflammation by co-activating microglia and astroglia, recruiting circulating lymphocytes and macrophages, and driving synaptic, neuritic, and myelin degeneration.^{23,59,156–161}

Biomarkers of Silent Disease Activity

Imaging Biomarkers

Paramagnetic Rim Lesions and Slowly Expanding Lesions

The persistent microglia/macrophage activity within the rim of CAL (Fig 2K1) and the associated axonal damage might represent 1 of the key components of the continuous, hidden, and deleterious inflammatory activity driving PIRA in MS. Over the past decade, an increasing clinical interest has been devoted to the detection of CAL as they are associated with higher disease severity and brain and spinal cord atrophy, thus representing a negative prognostic indicator for clinical worsening and disease progression.^{31,162–164}

A subset of CAL can now be visualized using susceptibility-sensitive MRI sequences, that is, T2* and phase contrast, R2* (Fig 2K2,K3) or quantitative susceptibility mapping (QSM), as non-enhancing lesions with a paramagnetic rim (termed “paramagnetic rim lesions” or PRL). MRI-neuropathological studies consistently showed that the magnetic susceptibility contrast at the lesion rim is mainly related to iron accumulation within activated microglia/macrophages.^{20,26,162,165–167}

While activated microglia/macrophages play a crucial role in myelin and debris clearance (a critical step for repair and remyelination), in the context of the highly inflammatory and dysregulated environment at the CAL edge, these immune cell populations are believed to be exerting a further detrimental role, as recently demonstrated by single-nucleus RNAseq phenotyping.²³

A recent pooled-data analysis of 31 published MRI studies highlighted that PRL are present in ~50% of relapsing and ~60% of progressive patients.¹⁶⁸ Compared to non-PRL, PRL are more destructive lesions, as reflected by significantly longer T1 times, decreased R2*,¹⁶⁹ reduced myelin water fractions, and low neurite dispersion index.^{166,170} In longitudinal MRI studies, PRL has been found to persist for years,¹⁷¹ and a subset of them slowly expand over time.^{20,162} Little is known regarding the

long-term dynamics of PRL and their response to current DMTs, but susceptibility reduction of the rim over a median time frame of 7 years has been reported.^{23,28}

A recent 4-year longitudinal study of 445 patients directly evaluated the role of PRL in PIRA: patients treated with anti-CD20 antibodies experiencing PIRA at follow-up had higher baseline PRL count.¹⁷²

Alternative candidate biomarkers of CAL are the slowly expanding lesions (SEL) representing the subset of non-enhancing chronic lesions showing radial and linear expansion over 1–2 years. SEL are identified by applying Jacobian determinant algorithms (non-linear deformation) to registered T1-weighted and T2-FLAIR images on at least three time-points. The computed radial and linear lesion expansion has been interpreted as lesion expansion. No histopathological validation has been provided for SEL quantified by the Jacobian determinant algorithm, and pathological processes other than inflammatory demyelination might explain the imaging finding (i.e., Wallerian neurodegeneration, and microvascular comorbidities). SEL have been detected in both relapsing and progressive MS patients, and they were shown to predict disability and progression at 7 and 9 years of follow-up.^{173–175} Modest effects on SEL were seen in MS patients treated by current disease-modifying therapies.^{173,176–178}

The limited overlap between PRL and SEL is a matter of current debate; in a recent study,¹⁷⁹ PRL satisfying the mathematical definition of SEL (39% of all PRL) showed microstructural tissue degeneration tissue over 72 weeks. A possible explanation for the discrepancy between the 2 biomarkers is that a subset of SEL has low iron content and, therefore, is not visible as PRL. In addition, recent imaging studies validated that not all CALs correspond to SELs or PRLs. Still, when PRLs are colocalized with SELs, they show expansion and worsening microstructural damage over time,¹⁷⁹ supporting a key role of smoldering inflammation in accumulating neurodegeneration and disease progression.¹⁷⁹

Brain and Grey Matter Atrophy

MRI changes in brain volume have proven clinical relevance in MS (Fig 2H1–H10) as a marker of irreversible tissue loss (i.e., brain atrophy).¹⁸⁰ Several studies have consistently shown that brain atrophy rates are higher in patients with MS than in healthy subjects since the earliest disease stage. Atrophy appears diffuse in the MS brain and spinal cord, particularly in subcortical and cortical regions, possibly reflecting the early neuroaxonal involvement.¹⁸¹

Compared with clinically stable patients, patients with PIRA had an increased rate of brain volume loss, mainly driven by cerebral GM loss (Fig 2H1–H10). Moreover, MS patients with PIRA had similar brain

atrophy⁶ and cortical thinning and deep GM volume loss rates¹⁸² to those patients experiencing disability accumulation due to relapses. Interestingly, these studies independently suggested that atrophy rates could be partially dissociated from relapse activity and likely to reflect mechanisms leading to the silent progression of MS.

Complementary to the brain atrophy assessment, the ‘brain-age’ paradigm¹⁸³ utilizes the relationship between disease and healthy brain structural ageing to understand the impact of diseases. The difference between an individual’s chronological age and the brain-predicted age (brain-PAD or brain age gap) has been proposed as an age-adjusted index of structural brain health. Using 3D T1-weighted MRI and machine learning algorithms, the brain-age paradigm offers the advantage of setting a subject’s state in the context of a normal population with an easily interpreted figure. MS has a pronounced effect on the brain-PAD metric, indicative of poor structural brain health. Furthermore, measures of brain-predicted age increase more rapidly than usual chronological ageing in both RR and progressive MS, implying that the brain-age approach is sensitive to accelerations in MS brain atrophy.¹⁸⁴ Recently, brain age was associated with the worsening of the Symbol Digit Modality Test (SDMT) performance.¹⁸⁵

Focal Cortical Demyelination

Substantial immunopathological (Fig 2F1) and imaging (Fig 2F2) evidence confirmed that focal demyelination occurs in MS since the early phases of the disease within both the cortical and deep GM, accumulates over time and provides a good clinical correlate in terms of disability accumulation.^{10,36,54,101,186}

CLs are at least partly independent of WM acute demyelination^{88,187} and usually do not show contrast enhancement.³⁶ The focal cortical damage is associated with a progression of physical and cognitive disability independently of relapse^{186,188–190} and its occurrence at clinical onset predicts a greater risk of disability progression.^{186,190–192}

A 30-year longitudinal study indicated the focal cortical demyelination as 1 of the primary substrates of disease progression, with CLs’ burden alone explaining 43% of the variance of the expanded disability status scale (EDSS).⁸⁹ On the contrary, a study on “benign MS” revealed that after 15 years of the disease, those patients who still demonstrated scarce disability progression and cognitive preservation showed a remarkably lower CLs number compared to early RRMS.¹⁹² In line with these data, the lesions of deep GM, especially the thalamic lesions, have been associated with disability progression being greater in progressive MS compared to RRMS.¹⁹³

Taken together, data suggest that cortical and deep GM lesions are expressions of complex “smoldering” pathological processes and contribute to the development of the PIRA.

Nevertheless, although current imaging protocols using double inversion recovery (DIR), phase sensitive inversion recovery (PSIR), or T2* weighted and magnetization-prepared rapid gradient-echo (MPRAGE) sequences at ultra-high field MRI (i.e., 7 T) have substantially improved their detection, most of the GM lesions remain undetectable in vivo.¹⁹⁴

Spinal Cord Damage

Spinal cord involvement is gaining attention as a critical region for explaining the disability progression (Fig 2J1–J3, I1–I3). The prognostic relevance of isolated spinal cord lesions (SCL) for developing a progressive disease course has been shown by studying extreme disease cases. Patients with solitary demyelinating lesions involving the spinal cord or cervical-medullary/brainstem regions developed an early progressive disease course.¹⁹⁵ In addition, in subjects with radiological isolated syndrome (RIS), SCL increased the risk of evolving to PPMS rather than RRMS.¹⁹⁶ From the analysis of conventional MRI sequences, a few imaging features have been identified that can contribute to the early identification of those patients who will develop a progressive MS course or accumulate more severe disability. These include the presence of diffuse signal hyperintensities on proton-density weighted sequences (i.e., abnormal areas of intermediate signal intensity between that of focal lesions and normal-appearing spinal cord, lacking a well-demarcated border from the adjacent normal-appearing cord)^{197,198} and the involvement of cord central GM (Fig 2J1–J3).^{199–201} Harboring spinal cord lesions is an important prognostic factor in identifying CIS patients with a shorter time to conversion to MS,²⁰² more severe accumulation of clinical disability²⁰³ and evolution to SPMS after 15 years of follow-up.²⁰⁴ Using quantitative MRI techniques, such as magnetisation transfer MRI,²⁰⁵ a gradient of microstructural damage in the outer surface of the cord, which might reflect the presence of subpial demyelination, was found in patients with MS and was more severe among those with a progressive phenotype. A recent 7 T study²⁰⁶ found that SCL have a greater propensity to occur closer to the central canal and subpial CSF interfaces, with a different behavior according to MS clinical phenotype (more involvement of central canal in progressive MS and of the outer subpial surface in RRMS).

In addition to focal demyelinating lesions, irreversible tissue loss (i.e., atrophy) in the spinal cord can be seen among MS patients. Spinal cord atrophy (Fig 2I1–I3)

occurs in all MS clinical phenotypes, is more pronounced and diffuse in progressive rather than relapsing MS patients, is associated with concurrent clinical disability and tends to progress over time.^{207,208} While a significant relationship is present between cord atrophy and accumulating disability in the short-term,^{209–211} it disappears at longer clinical follow-up (more than 10 years), suggesting that spinal cord atrophy may be critical for clinical deterioration in the first years of the disease. However, it might subsequently reach a ceiling effect.^{212–214} A recent study with 12 years of follow-up found that RRMS patients who developed SPMS had faster cord atrophy rates (−2.19% per year) at least 4 years before conversion compared to those patients who remained RRMS (−0.88% per year).²¹⁴ A faster spinal cord atrophy rate was associated with a shorter time to silent progression and SPMS conversion, challenging the traditional dichotomy of an RRMS and subsequent SPMS phenotype.

New Promising Imaging Biomarkers to Identify the Disease Progression

The Neurite Orientation Dispersion and Density Imaging. The neurite orientation dispersion and density imaging (NODDI) is a diffusion-weighted multi-shell MRI model that provides specific measures of tissue microstructure (Fig 2E2). These include the intracellular volume fraction (ICV_f)/neurite density index (NDI), reflecting neurite density, and orientation dispersion index (ODI), quantifying neurite orientation variability and tissue coherence and complexity.²¹⁵ In a recent study, PRL showed decreased myelin water fraction but also NDI relative to lesions without a rim,²¹⁶ confirming the pathological evidence of ongoing demyelination and axonal damage in these lesions.^{34,217} Significantly lower ICV_f/NDI in the NAWM^{218,219} and cortex,^{216,218–220} and ODI in the cortex^{219,220} were found in progressive compared to RRMS patients, and they correlated with more severe clinical disability, thus confirming in vivo that a clinically relevant progressive neurite loss and a simplification of dendritic arborization may contribute to the disease severity.^{219,220}

Constrained spherical deconvolution (CSD) is another diffusion-weighted multi-shell MRI model that allows to define the fiber-bundle cross-section area, a marker of axonal shrinkage/loss across a plane perpendicular to the fiber-bundle axis that may better quantify the degeneration of the WM fiber-bundles.^{221,222} A significant reduction of fiber-bundle cross-section area, gradually worsening over 1 year and reflecting more severe WM tract volume loss, has been found in progressive compared to RRMS patients,^{223,224} mainly involving clinically relevant WM tracts, including the cerebellar peduncles, the cortico-spinal tract, the cingulum and the corpus

callosum. Moreover, a lower fiber-bundle cross-section area in the NAWM and in the sensorimotor WM tracts was found to be significantly correlated with more severe clinical disability²²³ and with gait and motor control impairment, respectively.²²⁵

Soma and neurite density imaging (SANDI) is another model that may estimate not only MRI signal fractions attributed to neurites ($f_{neurite}$), but also of bodies of any CNS cell (f_{soma}).²²⁶ Two recent studies showed that, compared to HC, MS patients were characterized by significantly lower $f_{neurite}$ both in the NAWM and GM and lower f_{soma} in their GM.^{227,228} These microstructural abnormalities were significantly more severe in progressive MS patients,²²⁷ and they were associated with a more severe clinical disability and structural brain damage.^{227,228}

Nonetheless, the feasibility of these advanced diffusion-weighted multi-shell MRI model in the clinical setting is limited. Longitudinal studies are still needed to further explore the correlation between their derived measure changes and MS progression.

Leptomeningeal Enhancement. Leptomeningeal enhancement (LME, (Fig 2E2), Fig 2G1–G3), typically visualized on delayed post-contrast FLAIR MRI, has been recently explored as a biomarker for blood-meningeal barrier opening and meningeal inflammation in MS.^{10,229}

LME detection on post-contrast 7 T FLAIR is more prevalent than on 3 T FLAIR, occurs at frequencies closer to histopathologic data and allows the investigation of the relationship between meningeal inflammation and cortical pathology.²³⁰

Two patterns of LME have been described: “nodular”, with discrete, spherical nodules at the pial surface or subarachnoid space, and “spread/fill” with the appearance of contrast spread through the local subarachnoid space.²³⁰ In a recent meta-analysis including 1,605 MS patients, the proportion of patients with LME was higher in progressive than in the relapsing MS group (39.8% vs. 53.4%).²³¹ LME is associated with a more severe MS course and disease progression,^{230,232–235} with the extent of cortical,²³⁴ thalamic,²³⁴ and hippocampal²³⁶ lesions and with the rate of brain and cortical atrophy.^{230,232,233,236} However, LME is not specific to MS, as it has also been described in aged healthy controls^{230,237,238} as well as in patients with other inflammatory and infective neurologic conditions.^{231,237,239–241}

Positron Emission Tomography. Using radiotracers binding to the TSPO, a mitochondrial protein upregulated in activated microglial/macrophage and astrocytes activation, several PET studies have consistently demonstrated that increased glial activation could be detected not only in

active WM lesions but also, to a lesser extent, in CLs, and a subset of chronic WM lesions (possibly CAL).^{32,242–249} The number and volume of lesions with positive PET TSPO uptake were higher in progressive than in RRMS patients and correlated with the development of clinical disability²⁴² and with WM lesions accumulation. Using 18F-DPA7142, a fluorinated second-generation TSPO radioligand, more than half of WM lesions (53%) showed a homogeneously active core, and their number was the best predictor of cortical atrophy and disability progression over 2 years.²⁵⁰

TSPO PET also revealed a more diffuse brain inflammatory component in the NAWM, thalamus and cortex.^{242–249,251,252} Consistently with pathological findings,⁸⁸ such widespread glial-microglial activation was higher in patients with a more severe disability and a progressive disease course, correlated with structural brain damage,^{242–249} and predicted disability progression up to 4 years later.²⁴³

Fluid Biomarkers

Potential Biomarkers of Neuroaxonal Degeneration

Neurofilaments are polymeric proteins constituting microtubules and microfilaments in the neuronal cytoskeleton, providing structural support for axons. They consist of 3 subunits, according to their molecular weight, named “high,” “intermediate,” and “light,” which are liberated in the extracellular space after axonal damage. Although in MS, high CSF NfL levels were consistently and convincingly associated with gadolinium-enhancing lesions and relapses²⁵³, data on their association PIRA are less robust. Nevertheless, several studies suggested a relationship between serum NFL and the development of progressive disease, lower total and deep GM volume, lower mean cortical thickness, and higher T2 lesion count.^{254–256}

Moreover, a recently very elegant study aimed at determining whether and when NFL levels are elevated in the context of confirmed disability worsening suggested a clear relationship between the NFL levels and the risk of disability worsening not related to disease activity.²⁵⁷ An NFL z score greater than 1.0 was associated with a higher risk of diagnosing confirmed disability progression not related to relapse activity in less than 24 months.²⁵⁷ All these data suggested that sNFL could be a useful tool for the early identification of patients at risk of worse disease outcomes associated with relapse-associated worsening but also with the PIRA.

Similarly, the degree of cortical neurodegeneration can be detected by measuring the CSF protein levels of parvalbumin (PVALB), a calcium-binding protein

expressed by a subset of GABAergic inhibitory cortical interneurons, classified as fast-spiking interneurons. They were found reduced in layer II of the primary motor cortex of MS patients, particularly within the NAGM.⁹² Increased CSF PVALB levels in MS have been demonstrated to reflect interneuron loss, cortical atrophy, and severe cognitive decline in MS patients, both at the time of diagnosis and, increasing with progression, at the time of death.¹³⁶

Inflammatory Biomarkers of Glia Activity and Chronic Inflammation

In addition to specific markers of neuronal damage, several inflammatory biomarkers related to glial or immune cell activity in MS have been recently analyzed, and at the moment, a wide range of new biomarkers that can predict disability progression, monitor disease activity, and assess treatment response have been proposed.

Although kappa free light chain (KFLC) index has become a useful diagnostic biomarker in MS, in a very recent retrospectively identified based on 131 patients with clinically isolated syndrome or early RRMS, the KFLC index was observed to be significantly higher in PIRA compared with non-PIRA.²⁵⁸

Serum levels of glial fibrillary acidic protein (sGFAP), a protein highly expressed by astrocytes, were associated with disease progression in RRMS,²⁵⁹ and disability worsening in PP²⁶⁰; more recently, in a study including 355 patients and 259 healthy controls, patients with worsening progressive MS showed 50.9% higher sGFAP levels compared with those with stable MS suggesting that GFAP can be a prognostic biomarker for future PIRA.²⁶¹ Differently from sNFL, sGFAP does not typically elevate during acute inflammation but reflects accelerated GM brain volume loss and is associated with a higher risk of confirmed disability worsening.²⁶¹ Notably, GFAP age and sex specific normal ranges are advocated as well as a “gold standard” detection method.²⁶⁰

Increased CSF levels of activin A, a molecule expressed by activated microglia (42), which is part of the senescence-associated secretome, may indicate that MS patients enter an early inflammation process that could be at least partly responsible for the silent disease activity among MS patients older than 45 years.⁵⁵

While IL12p40 and CHI3L1, expressed by immune cells of the myeloid lineage, have been proposed as promising CSF biomarkers of MS lesional activity,²⁶² increased CSF levels of CHI3L1 have been specifically observed in patients with a higher burden of chronic active lesions.²⁶³ In addition, specific CSF protein profiles, including high protein levels of proinflammatory cytokines (TNF α , IFN γ , IL6), molecules involved in lymphoid neogenesis

(CXCL12, CXCL13, TNF), and B cell and plasma cell/blast activity (IL6, IL10, TNF, BAFF, APRIL, LIGHT, TWEAK), were found associated with elevated GM lesion load either in progressive post-mortem MS cases or in naive MS patients at the time of diagnosis.¹³⁵ The same CSF inflammatory pattern was proposed to predict a higher risk of disease activity and more severe cortical damage.¹³⁶ A composite biomarker study on a large and multicenter MS population could validate all the previous studies to better identify each patient's disease state since the diagnosis is needed. A new approach integrating all the serum and CSF analyses of an extensive pattern of biomarkers with demographic, clinical, imaging, cellular, metabolomics, microbiome, genomics, and proteomics data with new bioinformatics and machine learning will help to identify also patient subgroups with high risk of PIRA outcome.

Conclusions for the Clinical Practice

It is now clear that the pathological mechanisms underlying clinical progression begin early in the disease course. However, they are usually so gradual that the progression is initially unnoticed by physicians.^{6,264}

The recent finding that patients with pediatric-onset are less likely to exhibit PIRA over a decade of follow-up might correlate with their protection against disability,²⁶⁵ possibly for repair capacity and for the different immunopathological mechanisms.

The accuracy in PIRA detection is also challenged by concurrent relapses with variable degrees of recovery, raising the need to monitor patients with additional visits that become necessary, mainly when defining confirmed disability accumulation at 3- or 6-month follow-up.

Composite measures, including T25FW and 9HPT, should be adopted, given the notable percentage of disability accumulation detected by such measures.²

All the studies so far available,^{2,3,5,6} clearly suggested the need for strict clinical monitoring based on cognitive evaluation, which includes measures of information processing speed (as SDMT). From the imaging point of view, longitudinal measures of whole and regional atrophy, especially of cortical GM,^{6,182} and PRL are associated with PIRA, and look like promising markers for clinical practice.^{162,168,186,195}

Understanding whether fluid markers could help predict the PIRA represents a novel goal of precision medicine. sNFL and sGFAP have been suggested as potential candidates,²⁶¹ with a great effort undergoing their application at a single-patient level, but they are still not applicable to predict PIRA in a clinical context.²⁶⁶ CSF inflammatory markers, such as TNF, IFN γ , and molecules associated with B cell recruitment, have been not only

related to cortical damage but also demonstrated the capability to predict subsequent EDSS accumulation and cortical thinning, with additional predictive value to commonly adopted clinical and MRI measures.¹³⁶ Similarly, CSF inflammatory markers could be adapted to predict MS treatment response better,²⁶⁷ suggesting their ability to identify patients responding to specific drugs according to their mechanisms or disease endophenotypes.^{135,136,268}

We believe there is an urgent need to (1) improve the awareness about PIRA in the neurological community and improve its detection in clinical practice; (2) better define the role of MRI and fluid markers to predict PIRA; and (3) validate, integrate these markers, and finally translate them into clinical practice for a precision medicine approach.

Author Contributions

M.C., P.P., A.S., E.C., D.M., M.A., M.B., N.D.S., M.D.F., S.H., O.W.H., M.I., H.L., R.M., R.N., R.R., M.A.R., A.T., M.V., L.M.V., M.F., and R.M. contributed to the conception and design of the study; M.C., P.P., A.S., E.C., D.M., M.A., M.B., N.D.S., M.D.F., S.H., O.W.H., M.I., H.L., R.M., R.N., R.R., M.A.R., A.T., M.V., L.M.V., M.F., and R.M. contributed to the acquisition and analysis of data; M.C., P.P., A.S., E.C., D.M., M.A., M.B., N.D.S., M.D.F., S.H., O.W.H., M.I., H.L., R.M., R.N., R.R., M.A.R., A.T., M.V., L.M.V., M.F., and R.M. contributed to drafting the text or preparing the figures.

Potential Conflicts of Interest

M.C., P.P., A.S., E.C., D.M., M.A., M.B., N.D.S., M.D.F., S.H., O.W.H., M.I., H.L., R.M., R.N., R.R., M.A.R., A.T., M.V., L.M.V., M.F., and R.M. have nothing to report.

References

- Lublin FD, Reingold SC, Cohen JA, et al. Defining the clinical course of multiple sclerosis: The 2013 revisions. *Neurology* 2014; 83:278–286.
- Kappos L, Wolinsky JS, Giovannoni G, et al. Contribution of relapse-independent progression vs relapse-associated worsening to overall confirmed disability accumulation in typical relapsing multiple sclerosis in a pooled analysis of 2 randomized clinical trials. *JAMA Neurol* 2020;77:1132–1140.
- Lublin FD, Häring DA, Ganjgahi H, et al. How patients with multiple sclerosis acquire disability. *Brain* 2022;145:3147–3161.
- Giovannoni G, Popescu V, Wuerfel J, et al. Smouldering multiple sclerosis: the “real MS”. *Ther Adv Neurol Disord* 2022;15: 17562864211066752.
- Portaccio E, Bellinva A, Fonderico M, et al. Progression is independent of relapse activity in early multiple sclerosis: a real-life cohort study. *Brain* 2022;145:2796–2805.
- Cree BAC, Hollenbach JA, Bove R, et al. Silent progression in disease activity-free relapsing multiple sclerosis. *Ann Neurol* 2019;85: 653–666.
- Damasceno A, Damasceno BP, Cendes F. No evidence of disease activity in multiple sclerosis: Implications on cognition and brain atrophy. *Mult Scler* 2016;22:64–72.
- Motyl J, Friedova L, Vaneckova M, et al. Isolated cognitive decline in neurologically stable patients with multiple sclerosis. *Diagnostics (Basel)* 2021;11:464.
- Feuillet L, Reuter F, Audoin B, et al. Early cognitive impairment in patients with clinically isolated syndrome suggestive of multiple sclerosis. *Mult Scler* 2007;13:124–127.
- Howell OW, Reeves CA, Nicholas R, et al. Meningeal inflammation is widespread and linked to cortical pathology in multiple sclerosis. *Brain* 2011;134:2755–2771.
- Lassmann H. Pathogenic mechanisms associated with different clinical courses of multiple sclerosis. *Front Immunol* 2019;10:428340.
- Monaco S, Nicholas R, Reynolds R, Magliozzi R. Intrathecal inflammation in progressive multiple sclerosis. *Int J Mol Sci* 2020;21:1–11.
- Absinta M, Lassmann H, Trapp BD. Mechanisms underlying progression in multiple sclerosis. *Curr Opin Neurol* 2020;33:277–285.
- Papadopoulos D, Magliozzi R, Mitsikostas DD, et al. Aging, cellular senescence, and progressive multiple sclerosis. *Front Cell Neurosci* 2020;14:178.
- Ransohoff RM. Multiple sclerosis: role of meningeal lymphoid aggregates in progression independent of relapse activity. *Trends Immunol* 2023;44:266–275.
- Lucchinetti C, Bruck W, Parisi J, et al. Heterogeneity of multiple sclerosis lesions: Implications for the pathogenesis of demyelination. *Ann Neurol* 2000;47:707–717.
- Tobin WO, Kalinowska-Lyszczarz A, Weigand SD, et al. Clinical correlation of multiple sclerosis immunopathologic subtypes. *Neurology* 2021;97:E1906–E1913.
- Metz I, Gavrilova RH, Weigand SD, et al. Magnetic resonance imaging correlates of multiple sclerosis immunopathological patterns. *Ann Neurol* 2021;90:440–454.
- Heß K, Starost L, Kieran NW, et al. Lesion stage-dependent causes for impaired remyelination in MS. *Acta Neuropathol* 2020;140: 359–375.
- Dal-Bianco A, Grabner G, Kronnerwetter C, et al. Slow expansion of multiple sclerosis iron rim lesions: pathology and 7 T magnetic resonance imaging. *Acta Neuropathol* 2017;133:25–42.
- Bunyan RF, Popescu BFG, Carter JL, et al. Childhood-onset multiple sclerosis with progressive dementia and pathological cortical demyelination. *Arch Neurol* 2011;68:525–528.
- Bagnato F, Hametner S, Welch EB. Visualizing iron in multiple sclerosis. *Magn Reson Imaging* 2013;31:376–384.
- Absinta M, Maric D, Gharagozloo M, et al. A lymphocyte-microglia-astrocyte axis in chronic active multiple sclerosis. *Nature* 2021;597:709–714.
- Zrzavy T, Hametner S, Wimmer I, et al. Loss of “homeostatic” microglia and patterns of their activation in active multiple sclerosis. *Brain* 2017;140:1900–1913.
- Jäckle K, Zeis T, Schaeren-Wiemers N, et al. Molecular signature of slowly expanding lesions in progressive multiple sclerosis. *Brain* 2020;143:2073–2088.
- Absinta M, Sati P, Schindler M, et al. Persistent 7-tesla phase rim predicts poor outcome in new multiple sclerosis patient lesions. *J Clin Invest* 2016;126:2597–2609.
- Farb R, Rovira À. Hydrocephalus and CSF Disorders. *Diseases of the Brain, Head and Neck, Spine 2020–2023 Diagnostic Imaging*, US: Springer, 2020:11–24.

28. Dal-Bianco A, Grabner G, Kronnerwetter C, et al. Long-term evolution of multiple sclerosis iron rim lesions in 7 T MRI. *Brain* 2021;144:833–847.
29. Kornek B, Storch MK, Weissert R, et al. Multiple sclerosis and chronic autoimmune encephalomyelitis: a comparative quantitative study of axonal injury in active, inactive, and remyelinated lesions. *Am J Pathol* 2000;157:267–276.
30. Maggi P, Kuhle J, Schädelin S, et al. Chronic White Matter Inflammation and Serum Neurofilament Levels in Multiple Sclerosis. *Neurology* 2021;97:e543–e553.
31. Dal-Bianco A, Schranzer R, Grabner G, et al. Iron rims in patients with multiple sclerosis as neurodegenerative marker? A 7-Tesla Magnetic Resonance Study. *Front Neurol* 2021;12:12.
32. Kaunzner UW, Kang Y, Zhang S, et al. Quantitative susceptibility mapping identifies inflammation in a subset of chronic multiple sclerosis lesions. *Brain* 2019;142:133–145.
33. Starost L, Lindner M, Herold M, et al. Extrinsic immune cell-derived, but not intrinsic oligodendroglial factors contribute to oligodendroglial differentiation block in multiple sclerosis. *Acta Neuropathol* 2020;140:715–736.
34. Luchetti S, Fransen NL, van Eden CG, et al. Progressive multiple sclerosis patients show substantial lesion activity that correlates with clinical disease severity and sex: a retrospective autopsy cohort analysis. *Acta Neuropathol* 2018;135:511–528.
35. Gilmore CP, Donaldson I, Bo L, et al. Regional variations in the extent and pattern of grey matter demyelination in multiple sclerosis: a comparison between the cerebral cortex, cerebellar cortex, deep grey matter nuclei and the spinal cord. *J Neurol Neurosurg Psychiatry* 2009;80:182–187.
36. Calabrese M, Magliozzi R, Ciccarelli O, et al. Exploring the origins of grey matter damage in multiple sclerosis. *Nat Rev Neurosci* 2015;16:147–158.
37. Pardini M, Brown JWL, Magliozzi R, et al. Surface-in pathology in multiple sclerosis: a new view on pathogenesis? *Brain* 2021;144:1646–1654.
38. Peterson JW, Bö L, Mörk S, et al. Transected neurites, apoptotic neurons, and reduced inflammation in cortical multiple sclerosis lesions. *Ann Neurol* 2001;50:389–400.
39. Bø L, Vedeler CA, Nyland HI, et al. Subpial Demyelination in the Cerebral Cortex of Multiple Sclerosis Patients. *J Neuropathol Exp Neurol* 2003;62:723–732.
40. Magliozzi R, Howell O, Vora A, et al. Meningeal B-cell follicles in secondary progressive multiple sclerosis associate with early onset of disease and severe cortical pathology. *Brain* 2006;130:1089–1104.
41. Magliozzi R, Fadda G, Brown RA, et al. “Ependymal-in” Gradient of Thalamic Damage in Progressive Multiple Sclerosis. *Ann Neurol* 2022;92:670–685.
42. Cooze BJ, Dickerson M, Loganathan R, et al. The association between neurodegeneration and local complement activation in the thalamus to progressive multiple sclerosis outcome. *Brain Pathol* 2022;32:e13054.
43. Kutzelnigg A, Faber-Rod JC, Bauer J, et al. Widespread demyelination in the cerebellar cortex in multiple sclerosis. *Brain Pathol* 2007;17:38–44.
44. Howell OW, Schulz-Trieglaff EK, Carassiti D, et al. Extensive grey matter pathology in the cerebellum in multiple sclerosis is linked to inflammation in the subarachnoid space. *Neuropathol Appl Neurobiol* 2015;41:798–813.
45. Reali C, Magliozzi R, Roncaroli F, et al. B cell rich meningeal inflammation associates with increased spinal cord pathology in multiple sclerosis. *Brain Pathol* 2020;30:779–793.
46. Haider L, Zrzavy T, Hametner S, et al. The topography of demyelination and neurodegeneration in the multiple sclerosis brain. *Brain* 2016;139:807–815.
47. Guseo A, Jellinger K. The significance of perivascular infiltrations in multiple sclerosis. *J Neurol* 1975;211:51–60.
48. Serafini B, Rosicarelli B, Magliozzi R, et al. Detection of Ectopic B-cell Follicles with Germinal Centers in the Meninges of Patients with Secondary Progressive Multiple Sclerosis. *Brain Pathol* 2004;14:164–174.
49. Griffiths L, Reynolds R, Evans R, et al. Substantial subpial cortical demyelination in progressive multiple sclerosis: have we underestimated the extent of cortical pathology? *Neurol Neuroimmunol* 2020;7:51–67.
50. Gardner C, Magliozzi R, Durrenberger PF, et al. Cortical grey matter demyelination can be induced by elevated pro-inflammatory cytokines in the subarachnoid space of MOG-immunized rats. *Brain* 2013;136:3596–3608.
51. James RE, Schalks R, Browne E, et al. Persistent elevation of intrathecal pro-inflammatory cytokines leads to multiple sclerosis-like cortical demyelination and neurodegeneration. *Acta Neuropathol Commun* 2020;8:66.
52. Androdias G, Reynolds R, Chanal M, et al. Meningeal T cells associate with diffuse axonal loss in multiple sclerosis spinal cords. *Ann Neurol* 2010;68:465–476.
53. Ahmed SM, Fransen NL, Touil H, et al. Accumulation of meningeal lymphocytes correlates with white matter lesion activity in progressive multiple sclerosis. *JCI Insight* 2022;7:1–13.
54. Magliozzi R, Howell OW, Reeves C, et al. A Gradient of neuronal loss and meningeal inflammation in multiple sclerosis. *Ann Neurol* 2010;68:477–493.
55. Picón C, Tejada-Velarde A, Fernández-Velasco JI, et al. Identification of the immunological changes appearing in the csf during the early immunosenescence process occurring in multiple sclerosis. *Front Immunol* 2021;12:685139.
56. De Meo E, Storelli L, Moiola L, et al. In vivo gradients of thalamic damage in paediatric multiple sclerosis: a window into pathology. *Brain* 2021;144:186–197.
57. Jehna M, Pirpamer L, Khalil M, et al. Periventricular lesions correlate with cortical thinning in multiple sclerosis. *Ann Neurol* 2015;78:530–539.
58. Brown JWL, Pardini M, Brownlee WJ, et al. An abnormal periventricular magnetization transfer ratio gradient occurs early in multiple sclerosis. *Brain* 2017;140:387–398.
59. James Bates RE, Browne E, Schalks R, et al. Lymphotoxin-alpha expression in the meninges causes lymphoid tissue formation and neurodegeneration. *Brain* 2022;145:4287–4307.
60. Carassiti D, Altmann DR, Petrova N, et al. Neuronal loss, demyelination and volume change in the multiple sclerosis neocortex. *Neuropathol Appl Neurobiol* 2018;44:377–390.
61. Mahajan KR, Nakamura K, Cohen JA, et al. Intrinsic and extrinsic mechanisms of thalamic pathology in multiple sclerosis. *Ann Neurol* 2020;88:81–92.
62. Popescu V, Klaver R, Voorn P, et al. What drives MRI-measured cortical atrophy in multiple sclerosis? *Mult Scler* 2015;21:1280–1290.
63. Vercellino M, Plano F, Votta B, et al. Grey matter pathology in multiple sclerosis. *J Neuropathol Exp Neurol* 2005;64:1101–1107.
64. Wegner C, Esiri MM, Chance SA, et al. Neocortical neuronal, synaptic, and glial loss in multiple sclerosis. *Neurology* 2006;67:960–967.
65. Bevan RJ, Evans R, Griffiths L, et al. Meningeal inflammation and cortical demyelination in acute multiple sclerosis. *Ann Neurol* 2018;84:829–842.

66. Trapp BD, Vignos M, Dudman J, et al. Cortical neuronal densities and cerebral white matter demyelination in multiple sclerosis: a retrospective study. *Lancet Neurol* 2018;17:870–884.
67. Klaver R, Popescu V, Voorn P, et al. Neuronal and axonal loss in normal-appearing gray matter and subpial lesions in multiple sclerosis. *J Neuropathol Exp Neurol* 2015;74:453–458.
68. Papadopoulos D, Dukes S, Patel R, et al. Substantial archaocortical atrophy and neuronal loss in multiple sclerosis. *Brain Pathol* 2009;19:238–253.
69. Cifelli A, Arridge M, Jezzard P, et al. Thalamic neurodegeneration in multiple sclerosis. *Ann Neurol* 2002;52:650–653.
70. Vercellino M, Masera S, Lorenzatti M, et al. Demyelination, inflammation, and neurodegeneration in multiple sclerosis deep gray matter. *J Neuropathol Exp Neurol* 2009;68:489–502.
71. Vogt J, Paul F, Aktas O, et al. Lower motor neuron loss in multiple sclerosis and experimental autoimmune encephalomyelitis. *Ann Neurol* 2009;66:310–322.
72. Schirmer L, Albert M, Buss A, et al. Substantial early, but non-progressive neuronal loss in multiple sclerosis (MS) spinal cord. *Ann Neurol* 2009;66:698–704.
73. Schirmer L, Antel JP, Brück W, Stadelmann C. Axonal loss and neurofilament phosphorylation changes accompany lesion development and clinical progression in multiple sclerosis. *Brain Pathol* 2011;21:428–440.
74. Petrova N, Nutma E, Carassiti D, et al. Synaptic loss in multiple sclerosis spinal cord. *Ann Neurol* 2020;88:619–625.
75. Vercellino M, Marasciulo S, Grifoni S, et al. Acute and chronic synaptic pathology in multiple sclerosis gray matter. *Mult Scler* 2022;28:369–382.
76. Werneburg S, Jung J, Kunjamma RB, et al. Targeted complement inhibition at synapses prevents microglial synaptic engulfment and synapse loss in demyelinating disease. *Immunity* 2020;52:167–182.e7.
77. Freria CM, Zanon RG, Santos LMB, Oliveira ALR. Major histocompatibility complex class I expression and glial reaction influence spinal motoneuron synaptic plasticity during the course of experimental autoimmune encephalomyelitis. *J Comp Neurol* 2010;518:990–1007.
78. Mishra A, Kim HJ, Shin AH, Thayer SA. Synapse loss induced by interleukin-1 β requires pre- and post-synaptic mechanisms. *J Neuroimmune Pharmacol* 2012;7:571–578.
79. Yang G, Parkhurst CN, Hayes S, Gan WB. Peripheral elevation of TNF- α leads to early synaptic abnormalities in the mouse somatosensory cortex in experimental autoimmune encephalomyelitis. *Proc Natl Acad Sci U S A* 2013;110:10306–10311.
80. Jafari M, Schumacher AM, Snaidero N, et al. Phagocyte-mediated synapse removal in cortical neuroinflammation is promoted by local calcium accumulation. *Nat Neurosci* 2021;24:355–367.
81. van Olst L, Rodriguez-Mogeda C, Picon C, et al. Meningeal inflammation in multiple sclerosis induces phenotypic changes in cortical microglia that differentially associate with neurodegeneration. *Acta Neuropathol* 2021;141:881–899.
82. Trapp BD, Wujek JR, Criste GA, et al. Evidence for synaptic stripping by cortical microglia. *Glia* 2007;55:360–368.
83. Michailidou I, Willems JGP, Kooi EJ, et al. Complement C1q-C3-associated synaptic changes in multiple sclerosis hippocampus. *Ann Neurol* 2015;77:1007–1026.
84. Hammond JW, Bellizzi MJ, Ware C, et al. Complement-dependent synapse loss and microgliosis in a mouse model of multiple sclerosis. *Brain Behav Immun* 2020;87:739–750.
85. Mandolesi G, Grasselli G, Musella A, et al. GABAergic signaling and connectivity on Purkinje cells are impaired in experimental autoimmune encephalomyelitis. *Neurobiol Dis* 2012;46:414–424.
86. Dutta R, Chang A, Doud MK, et al. Demyelination causes synaptic alterations in hippocampi from multiple sclerosis patients. *Ann Neurol* 2011;69:445–454.
87. Jürgens T, Jafari M, Kreutzfeldt M, et al. Reconstruction of single cortical projection neurons reveals primary spine loss in multiple sclerosis. *Brain* 2016;139:39–46.
88. Kutzelnigg A, Lucchinetti CF, Stadelmann C, et al. Cortical demyelination and diffuse white matter injury in multiple sclerosis. *Brain* 2005;128:2705–2712.
89. Halder SK, Milner R. Hypoxia in multiple sclerosis; is it the chicken or the egg? *Brain* 2021;144:402–410.
90. Trapp BD, Stys PK. Virtual hypoxia and chronic necrosis of demyelinated axons in multiple sclerosis. *Lancet Neurol* 2009;8:280–291.
91. Licht-Mayer S, Campbell GR, Canizares M, et al. Enhanced axonal response of mitochondria to demyelination offers neuroprotection: implications for multiple sclerosis. *Acta Neuropathol* 2020;140:143–167.
92. Dutta R, McDonough J, Yin X, et al. Mitochondrial dysfunction as a cause of axonal degeneration in multiple sclerosis patients. *Ann Neurol* 2006;59:478–489.
93. Campbell GR, Ziabreva I, Reeve AK, et al. Mitochondrial DNA deletions and neurodegeneration in multiple sclerosis. *Ann Neurol* 2011;69:481–492.
94. Mahad DJ, Ziabreva I, Campbell G, et al. Mitochondrial changes within axons in multiple sclerosis. *Brain* 2009;132:1161–1174.
95. Mancini A, Tantucci M, Mazzocchetti P, et al. Microglial activation and the nitric oxide/cGMP/PKG pathway underlie enhanced neuronal vulnerability to mitochondrial dysfunction in experimental multiple sclerosis. *Neurobiol Dis* 2018;113:97–108.
96. Nikić I, Merkler D, Sorbara C, et al. A reversible form of axon damage in experimental autoimmune encephalomyelitis and multiple sclerosis. *Nat Med* 2011;17:495–499.
97. Leurs CE, Podlesniy P, Trullas R, et al. Cerebrospinal fluid mtDNA concentration is elevated in multiple sclerosis disease and responds to treatment. *Mult Scler* 2018;24:472–480.
98. Albanese M, Zagaglia S, Landi D, et al. Cerebrospinal fluid lactate is associated with multiple sclerosis disease progression. *J Neuroinflammation* 2016;13:36.
99. Yang R, Dunn JF. Multiple sclerosis disease progression: Contributions from a hypoxia-inflammation cycle. *Mult Scler* 2019;25:1715–1718.
100. Rosenkranz SC, Shaposhnykov AA, Träger S, et al. Enhancing mitochondrial activity in neurons protects against neurodegeneration in a mouse model of multiple sclerosis. *Elife* 2021;10:1–60.
101. Luchicchi A, Hart B, Frigerio I, et al. Axon-myelin unit blistering as early event in ms normal appearing white matter. *Ann Neurol* 2021;89:711–725.
102. Teo W, Capriarello AV, Morgan ML, et al. Nile Red fluorescence spectroscopy reports early physicochemical changes in myelin with high sensitivity. *Proc Natl Acad Sci U S A* 2021;118:e2016897118.
103. Zeis T, Schaeren-Wiemers N. Lame ducks or fierce creatures? - the role of oligodendrocytes in multiple sclerosis. *J Mol Neurosci* 2008;35:91–100.
104. Dzedzic T, Metz I, Dallenga T, et al. Wallerian degeneration: a major component of early axonal pathology in multiple sclerosis. *Brain Pathol* 2010;20:976–985.
105. Nave KA. Myelination and support of axonal integrity by glia. *Nature* 2010;468:244–252.
106. Wolswijk G, Balesar R. Changes in the expression and localization of the paranodal protein Caspr on axons in chronic multiple sclerosis. *Brain* 2003;126:1638–1649.

107. Gallego-Delgado P, James R, Browne E, et al. Neuroinflammation in the normal-appearing white matter (NAWM) of the multiple sclerosis brain causes abnormalities at the nodes of Ranvier. *PLoS Biol* 2020;18:e3001008.
108. Howell OW, Rundle JL, Garg A, et al. Activated microglia mediate axoglial disruption that contributes to axonal injury in multiple sclerosis. *J Neuropathol Exp Neurol* 2010;69:1017–1033.
109. Fu Y, Sun W, Shi Y, et al. Glutamate excitotoxicity inflicts paranodal myelin splitting and retraction. *PLoS One* 2009;4:e6705.
110. Sospedra M, Martin R. Immunology of multiple sclerosis. *Semin Neurol* 2016;36:115–127.
111. Li R, Rezk A, Miyazaki Y, et al. Proinflammatory GM-CSF-producing B cells in multiple sclerosis and B cell depletion therapy. *Sci Transl Med* 2015;7:310ra166.
112. Cencioni MT, Mattoscio M, Magliozzi R, et al. B cells in multiple sclerosis — from targeted depletion to immune reconstitution therapies. *Nat Rev Neurol* 2021;17:399–414.
113. Li R, Patterson KR, Bar-Or A. Reassessing B cell contributions in multiple sclerosis. *Nat Immunol* 2018;19:696–707.
114. Sospedra M, Martin R. Immunology of multiple sclerosis. *Annu Rev Immunol* 2005;23:683–747.
115. Bielekova B, Sung M-H, Kadom N, et al. Expansion and functional relevance of high-avidity myelin-specific CD4+ t cells in multiple sclerosis. *J Immunol* 2004;172:3893–3904.
116. Jelcic I, Al Nimer F, Wang J, et al. Memory B cells activate brain-homing, autoreactive CD4+ t cells in multiple sclerosis. *Cell* 2018;175:85–100.e23.
117. Planas R, Santos R, Tomas-Ojer P, et al. GDP-fucose synthase is a CD4+T cell-specific autoantigen in DRB3*02:02 patients with multiple sclerosis. *Sci Transl Med* 2018;10:eaat4301.
118. Bronge M, Högelin KA, Thomas OG, et al. Identification of four novel T cell autoantigens and personal autoreactive profiles in multiple sclerosis. *Sci Adv* 2022;8:eabn1823.
119. Thomas OG, Bronge M, Tengvall K, et al. Cross-reactive EBNA1 immunity targets alpha-crystallin B and is associated with multiple sclerosis. *Sci Adv* 2023;9:eadg3032.
120. Hu D, Notarbartolo S, Croonenborghs T, et al. Transcriptional signature of human pro-inflammatory TH17 cells identifies reduced IL10 gene expression in multiple sclerosis. *Nat Commun* 2017;8:1600.
121. Balashov KE, Rottman JB, Weiner HL, Hancock WW. CCR5+ and CXCR3+ T cells are increased in multiple sclerosis and their ligands MIP-1 α and IP-10 are expressed in demyelinating brain lesions. *Proc Natl Acad Sci* 1999;96:6873–6878.
122. van Langelaar J, van der Vuurst de Vries RM, Janssen M, et al. T helper 17.1 cells associate with multiple sclerosis disease activity: perspectives for early intervention. *Brain* 2018;141:1334–1349.
123. Asashima H, Axisa P-P, Pham THG, et al. Impaired TIGIT expression on B cells drives circulating follicular helper T cell expansion in multiple sclerosis. *J Clin Investig* 2022;132.
124. Planas R, Metz I, Ortiz Y, et al. Central role of Th2/Tc2 lymphocytes in pattern II multiple sclerosis lesions. *Ann Clin Transl Neurol* 2015;2:875–893.
125. Wang Q, Zhang Y, Wu L, et al. Structural and functional basis of SARS-CoV-2 Entry by Using Human ACE2. *Cell* 2020;181:894–904.e9.
126. van Langelaar J, Rijvers L, Janssen M, et al. Induction of brain-infiltrating T-bet-expressing B cells in multiple sclerosis. *Ann Neurol* 2019;86:264–278.
127. Sorensen PS, Sellebjerg F, Hartung HP, et al. The apparently milder course of multiple sclerosis: Changes in the diagnostic criteria, therapy and natural history. *Brain* 2020;143:2637–2652.
128. Ramesh A, Schubert RD, Greenfield AL, et al. A pathogenic and clonally expanded B cell transcriptome in active multiple sclerosis. *Proc Natl Acad Sci* 2020;117:22932–22943.
129. Lossius A, Vartdal F, Holmøy T. Vitamin D sensitive EBNA-1 specific T cells in the cerebrospinal fluid of patients with multiple sclerosis. *J Neuroimmunol* 2011;240–241:87–96.
130. Høglund RA, Bremel RD, Homan EJ, et al. CD4+ T cells in the blood of ms patients respond to predicted epitopes from B cell receptors found in spinal fluid. *Front Immunol* 2020;11:513196.
131. Planas R, Metz I, Martin R, Sospedra M. Detailed Characterization of T Cell Receptor Repertoires in Multiple Sclerosis Brain Lesions. *Front Immunol* 2018;9:328192.
132. Montalban X, Hauser SL, Kappos L, et al. Ocrelizumab versus placebo in primary progressive multiple sclerosis. *N Engl J Med* 2017;376:209–220.
133. Couloume L, Ferrant J, Le Gallou S, et al. Mass cytometry identifies Expansion of T-bet+ B Cells and CD206+ monocytes in early multiple sclerosis. *Front Immunol* 2021;12:653577.
134. Johansson D, Rauld C, Roux J, et al. mass cytometry of CSF Identifies an MS-associated B-cell population. *Neurol Neuroimmunol Neuroinflamm* 2021;8:e943.
135. Magliozzi R, Howell OW, Nicholas R, et al. Inflammatory intrathecal profiles and cortical damage in multiple sclerosis. *Ann Neurol* 2018;83:739–755.
136. Magliozzi R, Scalfari A, Pisani AI, et al. The CSF Profile Linked to Cortical Damage Predicts Multiple Sclerosis Activity. *Ann Neurol* 2020;88:562–573.
137. Machado-Santos J, Saji E, Tröscher AR, et al. The compartmentalized inflammatory response in the multiple sclerosis brain is composed of tissue-resident CD8+ T lymphocytes and B cells. *Brain* 2018;141:2066–2082.
138. Magliozzi R, Serafini B, Rosicarelli B, et al. B-cell enrichment and Epstein-Barr virus infection in inflammatory cortical lesions in secondary progressive multiple sclerosis. *J Neuropathol Exp Neurol* 2013;72:29–41.
139. Lisak RP, Benjamins JA, Nedelkoska L, et al. Secretory products of multiple sclerosis B cells are cytotoxic to oligodendroglia in vitro. *J Neuroimmunol* 2012;246:85–95.
140. Lisak RP, Nedelkoska L, Benjamins JA, et al. B cells from patients with multiple sclerosis induce cell death via apoptosis in neurons in vitro. *J Neuroimmunol* 2017;309:88–99.
141. Lovato L, Willis SN, Rodig SJ, et al. Related B cell clones populate the meninges and parenchyma of patients with multiple sclerosis. *Brain* 2011;134:534–541.
142. Colombo M, Dono M, Gazzola P, et al. Accumulation of clonally related b lymphocytes in the cerebrospinal fluid of multiple sclerosis patients. *J Immunol* 2000;164:2782–2789.
143. Baranzini SE, Jeong MC, Butunoi C, et al. B cell repertoire diversity and clonal expansion in multiple sclerosis brain lesions. *J Immunol* 1999;163:5133–5144.
144. von Büdingen H-C, Kuo TC, Sirota M, et al. B cell exchange across the blood-brain barrier in multiple sclerosis. *J Clin Investig* 2012;122:4533–4543.
145. Brioschi S, Wang W-L, Peng V, et al. Heterogeneity of meningeal B cells reveals a lymphopoietic niche at the CNS borders. *Science* 2021;373:eabf9277.
146. Steri M, Orrù V, Idda ML, et al. Overexpression of the cytokine BAFF and autoimmunity risk. *N Engl J Med* 2017;376:1615–1626.
147. Bjornevik K, Cortese M, Healy BC, et al. Longitudinal analysis reveals high prevalence of Epstein-Barr virus associated with multiple sclerosis. *Science* 2022;375:296–301.

148. Aloisi F, Giovannoni G, Salvetti M. Epstein-Barr virus as a cause of multiple sclerosis: opportunities for prevention and therapy. *Lancet Neurol* 2023;22:338–349.
149. Fischer MT, Wimmer I, Höftberger R, et al. Disease-specific molecular events in cortical multiple sclerosis lesions. *Brain* 2013;136:1799–1815.
150. Masuda T, Sankowski R, Staszewski O, Prinz M. Microglia heterogeneity in the single-cell era. *Cell Rep* 2020;30:1271–1281.
151. Scharzt ND, Tenner AJ. The good, the bad, and the opportunities of the complement system in neurodegenerative disease. *J Neuroinflammation* 2020;17:354.
152. Fitzgerald KC, Kim K, Smith MD, et al. Early complement genes are associated with visual system degeneration in multiple sclerosis. *Brain* 2019;142:2722–2736.
153. Roostaei T, Sadaghiani S, Mashhadi R, et al. Convergent effects of a functional C3 variant on brain atrophy, demyelination, and cognitive impairment in multiple sclerosis. *Mult Scler* 2019;25:532–540.
154. Ingram G, Loveless S, Howell OW, et al. Complement activation in multiple sclerosis plaques: an immunohistochemical analysis. *Acta Neuropathol Commun* 2014;2:1–15.
155. Watkins LM, Neal JW, Loveless S, et al. Complement is activated in progressive multiple sclerosis cortical grey matter lesions. *J Neuroinflammation* 2016;13:161.
156. Storch MK, Piddlesden S, Haltia M, et al. Multiple sclerosis: in situ evidence for antibody- and complement-mediated demyelination. *Ann Neurol* 1998;43:465–471.
157. Barnett MH, Parratt JDE, Cho ES, Prineas JW. Immunoglobulins and complement in postmortem multiple sclerosis tissue. *Ann Neurol* 2009;65:32–46.
158. Liddel SA, Guttenplan KA, Clarke LE, et al. Neurotoxic reactive astrocytes are induced by activated microglia. *Nature* 2017;541:481–487.
159. Gharagozloo M, Smith MD, Jin J, et al. Complement component 3 from astrocytes mediates retinal ganglion cell loss during neuroinflammation. *Acta Neuropathol* 2021;142:899–915.
160. Ramaglia V, Dubey M, Malpede MA, et al. Complement-associated loss of CA2 inhibitory synapses in the demyelinated hippocampus impairs memory. *Acta Neuropathol* 2021;142:643–667.
161. Evans R, Watkins LM, Hawkins K, et al. Complement activation and increased anaphylatoxin receptor expression are associated with cortical grey matter lesions and the compartmentalised inflammatory response of multiple sclerosis. *Front Cell Neurosci* 2023;17:1094106.
162. Absinta M, Sati P, Masuzzo F, et al. Association of chronic active multiple sclerosis lesions with disability in vivo. *JAMA Neurol* 2019;76:1474–1483.
163. Treaba CA, Conti A, Klawiter EC, et al. Cortical and phase rim lesions on 7 T MRI as markers of multiple sclerosis disease progression. *Brain Commun* 2021;3:fcab134.
164. Meaton I, Altokhis A, Allen CM, et al. Paramagnetic rims are a promising diagnostic imaging biomarker in multiple sclerosis. *Mult Scler* 2022;28:2212–2220.
165. Bagnato F, Hametner S, Yao B, et al. Tracking iron in multiple sclerosis: a combined imaging and histopathological study at 7 Tesla. *Brain* 2011;134:3599–3612.
166. Rahmzadeh R, Galbusera R, Lu P, et al. A new advanced MRI biomarker for remyelinated lesions in multiple sclerosis. *Ann Neurol* 2022;92:486–502.
167. Gillen KM, Mubarak M, Park C, et al. QSM is an imaging biomarker for chronic glial activation in multiple sclerosis lesions. *Ann Clin Transl Neurol* 2021;8:877–886.
168. Martire MS, Moiola L, Rocca MA, et al. What is the potential of paramagnetic rim lesions as diagnostic indicators in multiple sclerosis? *Expert Rev Neurother* 2022;22:829–837.
169. Harrison DM, Li X, Liu H, et al. Lesion heterogeneity on high-field susceptibility MRI is associated with multiple sclerosis severity. *Am J Neuroradiol* 2016;37:1447–1453.
170. Yao Y, Nguyen TD, Pandya S, et al. Combining quantitative susceptibility mapping with automatic zero reference (QSM0) and myelin water fraction imaging to quantify iron-related myelin damage in chronic active MS Lesions. *Am J Neuroradiol* 2018;39:303–310.
171. Bian W, Harter K, Hammond-Rosenbluth KE, et al. A serial *in vivo* 7T magnetic resonance phase imaging study of white matter lesions in multiple sclerosis. *Mult Scler J* 2013;19:69–75.
172. Maggi P, Vanden BC, Pedrini E, et al. B cell depletion therapy does not resolve chronic active multiple sclerosis lesions. *EBioMedicine* 2023;94:104701.
173. Elliott C, Belachew S, Wolinsky JS, et al. Chronic white matter lesion activity predicts clinical progression in primary progressive multiple sclerosis. *Brain* 2019;142:2787–2799.
174. Preziosa P, Pagani E, Meani A, et al. Slowly expanding lesions predict 9-year multiple sclerosis disease progression. *Neurol Neuroimmunol Neuroinflamm* 2022;9:e1139.
175. Calvi A, Tur C, Chard D, et al. Slowly expanding lesions relate to persisting black-holes and clinical outcomes in relapse-onset multiple sclerosis. *Neuroimage Clin* 2022;35:103048.
176. Preziosa P, Pagani E, Moiola L, et al. Occurrence and microstructural features of slowly expanding lesions on fingolimod or natalizumab treatment in multiple sclerosis. *Mult Scler J* 2021;27:1520–1532.
177. Calvi A, Carrasco FP, Tur C, et al. Association of slowly expanding lesions on MRI with disability in people with secondary progressive multiple sclerosis. *Neurology* 2022;98:e1783–e1793.
178. Arnold DL, Elliott C, Montalban X, et al. Effects of Evobrutinib, a Bruton's Tyrosine Kinase Inhibitor, on Slowly Expanding Lesions: An Emerging Imaging Marker of Chronic Tissue Loss in Multiple Sclerosis. *Mult Scler J* 2021;27:3–133.
179. Elliott C, Rudko DA, Arnold DL, et al. Lesion-level correspondence and longitudinal properties of paramagnetic rim and slowly expanding lesions in multiple sclerosis. *Mult Scler* 2023;29:680–690.
180. Sastre-Garriga J, Pareto D, Battaglini M, et al. MAGNIMS consensus recommendations on the use of brain and spinal cord atrophy measures in clinical practice. *Nat Rev Neurol* 2020;16:171–182.
181. Eshaghi A, Prados F, Brownlee WJ, et al. Deep gray matter volume loss drives disability worsening in multiple sclerosis. *Ann Neurol* 2018;83:210–222.
182. Cagol A, Schaedelin S, Barakovic M, et al. Association of Brain Atrophy with Disease Progression Independent of Relapse Activity in Patients with Relapsing Multiple Sclerosis. *JAMA Neurol* 2022;79:682–692.
183. Cole JH, Franke K. Predicting age using neuroimaging: innovative brain ageing biomarkers. *Trends Neurosci* 2017;40:681–690.
184. Cole PhD JH, Raffel MDJ, Friede PDT, et al. Longitudinal Assessment of Multiple Sclerosis with the Brain-Age Paradigm. *Ann Neurol* 2020;88:93–105.
185. Denissen S, Engemann DA, De Cock A, et al. Brain age as a surrogate marker for cognitive performance in multiple sclerosis. *Eur J Neurol* 2022;29:3039–3049.
186. Calabrese M, Poretto V, Favaretto A, et al. Cortical lesion load associates with progression of disability in multiple sclerosis. *Brain* 2012;135:2952–2961.

187. Bö L, Geurts JGG, van der Valk P, et al. Lack of correlation between cortical demyelination and white matter pathologic changes in multiple sclerosis. *Arch Neurol* 2007;64:76–80.
188. Harrison DM, Roy S, Oh J, et al. Association of cortical lesion burden on 7-T magnetic resonance imaging with cognition and disability in multiple sclerosis. *JAMA Neurol* 2015;72:1004–1012.
189. Nelson PT, Alafuzoff I, Bigio EH, et al. Correlation of Alzheimer disease neuropathologic changes with cognitive status: a review of the literature. *J Neuropathol Exp Neurol* 2012;71:362–381.
190. Ziccardi S, Pisani AI, Schiavi GM, et al. Cortical lesions at diagnosis predict long-term cognitive impairment in multiple sclerosis: A 20-year study. *Eur J Neurol* 2023;30:1378–1388.
191. Scalfari A, Romualdi C, Nicholas RS, et al. The cortical damage, early relapses, and onset of the progressive phase in multiple sclerosis. *Neurology* 2018;90:e2099–e2106.
192. Calabrese M, Favaretto A, Poretto V, et al. Low degree of cortical pathology is associated with benign course of multiple sclerosis. *Mult Scler J* 2013;19:904–911.
193. Calabrese M, Favaretto A, Martini V, Gallo P. Grey matter lesions in MS From histology to clinical implications. *Prion* 2013;7:20–27.
194. Mainero C, Treaba CA, Barbuti E. Imaging cortical lesions in multiple sclerosis. *Curr Opin Neurol* 2023;36:222–228.
195. Keegan BM, Kaufmann TJ, Weinschenker BG, et al. Progressive solitary sclerosis: Gradual motor impairment from a single CNS demyelinating lesion. *Neurology* 2016;87:1713–1719.
196. Kantarci OH, Lebrun C, Siva A, et al. Primary progressive multiple sclerosis evolving from radiologically isolated syndrome. *Ann Neurol* 2016;79:288–294.
197. Coret F, Bosca I, Landete L, et al. Early diffuse demyelinating lesion in the cervical spinal cord predicts a worse prognosis in relapsing-remitting multiple sclerosis. *Mult Scler* 2010;16:935–941.
198. Weier K, Mazraeh J, Naegelin Y, et al. Biplanar MRI for the assessment of the spinal cord in multiple sclerosis. *Mult Scler* 2012;18:1560–1569.
199. Eden D, Gros C, Badji A, et al. Spatial distribution of multiple sclerosis lesions in the cervical spinal cord. *Brain* 2019;142:633–646.
200. Valsasina P, Aboulwafa M, Preziosa P, et al. Cervical Cord T1-weighted hypointense lesions at mr imaging in multiple sclerosis: relationship to cord atrophy and disability. *Radiology* 2018;288:234–244.
201. Kearney H, Miszkiel KA, Yiannakas MC, et al. Grey matter involvement by focal cervical spinal cord lesions is associated with progressive multiple sclerosis. *Mult Scler* 2016;22:910–920.
202. Sombekke MH, Wattjes MP, Balk LJ, et al. Spinal cord lesions in patients with clinically isolated syndrome: a powerful tool in diagnosis and prognosis. *Neurology* 2013;80:69–75.
203. Arrambide G, Rovira A, Sastre-Garriga J, et al. Spinal cord lesions: A modest contributor to diagnosis in clinically isolated syndromes but a relevant prognostic factor. *Mult Scler* 2018;24:301–312.
204. Brownlee WJ, Altmann DR, Prados F, et al. Early imaging predictors of long-term outcomes in relapse-onset multiple sclerosis. *Brain* 2019;142:2276–2287.
205. Kearney H, Yiannakas MC, Samson RS, et al. Investigation of magnetization transfer ratio-derived pial and subpial abnormalities in the multiple sclerosis spinal cord. *Brain* 2014;137:2456–2468.
206. Ouellette R, Treaba CA, Granberg T, et al. 7 T imaging reveals a gradient in spinal cord lesion distribution in multiple sclerosis. *Brain* 2020;143:2973–2987.
207. Rocca MA, Horsfield MA, Sala S, et al. A multicenter assessment of cervical cord atrophy among MS clinical phenotypes. *Neurology* 2011;76:2096–2102.
208. Rocca MA, Valsasina P, Meani A, et al. Clinically relevant cranio-caudal patterns of cervical cord atrophy evolution in MS. *Neurology* 2019;93:E1852–E1866.
209. Lukas C, Knol DL, Sombekke MH, et al. Cervical spinal cord volume loss is related to clinical disability progression in multiple sclerosis. *J Neurol Neurosurg Psychiatry* 2015;86:410–418.
210. Tsagkas C, Magon S, Gaetano L, et al. Preferential spinal cord volume loss in primary progressive multiple sclerosis. *Mult Scler* 2019;25:947–957.
211. Tsagkas C, Naegelin Y, Amann M, et al. Central nervous system atrophy predicts future dynamics of disability progression in a real-world multiple sclerosis cohort. *Eur J Neurol* 2021;28:4153–4166.
212. Khaleeli Z, Ciccatelli O, Manfredonia F, et al. Predicting progression in primary progressive multiple sclerosis: a 10-year multicenter study. *Ann Neurol* 2008;63:790–793.
213. Rocca MA, Sormani MP, Rovaris M, et al. Long-term disability progression in primary progressive multiple sclerosis: A 15-year study. *Brain* 2017;140:2814–2819.
214. Bischof A, Papinutto N, Keshavan A, et al. Spinal cord atrophy predicts progressive disease in relapsing multiple sclerosis. *Ann Neurol* 2022;91:268–281.
215. Zhang H, Schneider T, Wheeler-Kingshott CA, Alexander DC. NODDI: practical in vivo neurite orientation dispersion and density imaging of the human brain. *Neuroimage* 2012;61:1000–1016.
216. Rahmzadeh R, Lu P-J, Barakovic M, et al. Myelin and axon pathology in multiple sclerosis assessed by myelin water and multi-shell diffusion imaging. *Brain* 2021;144:1684–1696.
217. Frischer JM, Weigand SD, Guo Y, et al. Clinical and pathological insights into the dynamic nature of the white matter multiple sclerosis plaque. *Ann Neurol* 2015;78:710–721.
218. Spano B, Giulietti G, Pisani V, et al. Disruption of neurite morphology parallels MS progression. *Neurol Neuroimmunol Neuroinflamm* 2018;5:e502.
219. Preziosa P, Pagani E, Meani A, et al. NODDI, diffusion tensor microstructural abnormalities and atrophy of brain white matter and gray matter contribute to cognitive impairment in multiple sclerosis. *J Neurol* 2023;270:810–823.
220. Preziosa P, Pagani E, Bonacchi R, et al. In vivo detection of damage in multiple sclerosis cortex and cortical lesions using NODDI. *J Neurol Neurosurg Psychiatry* 2022;93:628–636.
221. Jeurissen B, Tournier J-D, Dhollander T, et al. Multi-tissue constrained spherical deconvolution for improved analysis of multi-shell diffusion MRI data. *Neuroimage* 2014;103:411–426.
222. Raffelt DA, Tournier J-D, Smith RE, et al. Investigating white matter fibre density and morphology using fixel-based analysis. *Neuroimage* 2017;144:58–73.
223. Storelli L, Pagani E, Meani A, et al. Advanced diffusion-weighted imaging models better characterize white matter neurodegeneration and clinical outcomes in multiple sclerosis. *J Neurol* 2022;269:4729–4741.
224. Storelli L, Pagani E, Preziosa P, et al. Measurement of white matter fiber-bundle cross-section in multiple sclerosis using diffusion-weighted imaging. *Mult Scler J* 2021;27:818–826.
225. Strik M, Cofré Lizama LE, Shanahan CJ, et al. Axonal loss in major sensorimotor tracts is associated with impaired motor performance in minimally disabled multiple sclerosis patients. *Brain Commun* 2021;3:fcab032.
226. Palombo M, Ianus A, Guerreri M, et al. SANDI: A compartment-based model for non-invasive apparent soma and neurite imaging by diffusion MRI. *Neuroimage* 2020;215:116835.
227. Margoni M, Pagani E, Preziosa P, et al. In vivo quantification of brain soma and neurite density abnormalities in multiple sclerosis. *J Neurol* 2023;270:433–445.

228. Krijnen EA, Russo AW, Salim Karam E, et al. Detection of grey matter microstructural substrates of neurodegeneration in multiple sclerosis. *Brain Commun* 2023;5:fcad153.
229. Choi SR, Howell OW, Carassiti D, et al. Meningeal inflammation plays a role in the pathology of primary progressive multiple sclerosis. *Brain* 2012;135:2925–2937.
230. Harrison DM, Wang KY, Fiol J, et al. Leptomeningeal enhancement at 7T in multiple sclerosis: frequency, morphology, and relationship to cortical volume. *J Neuroimaging* 2017;27:461–468.
231. Ineichen BV, Tsagkas C, Absinta M, Reich DS. Leptomeningeal enhancement in multiple sclerosis and other neurological diseases: A systematic review and Meta-Analysis. *Neuroimage Clin* 2022;33:102939.
232. Zivadinov R, Ramasamy DP, Vaneckova M, et al. Leptomeningeal contrast enhancement is associated with progression of cortical atrophy in MS: A retrospective, pilot, observational longitudinal study. *Mult Scler* 2017;23:1336–1345.
233. Makshakov G, Magonov E, Totolyan N, et al. Leptomeningeal contrast enhancement is associated with disability progression and grey matter atrophy in multiple sclerosis. *Neurol Res Int* 2017;2017:1–7.
234. Zurawski J, Tauhid S, Chu R, et al. 7T MRI cerebral leptomeningeal enhancement is common in relapsing-remitting multiple sclerosis and is associated with cortical and thalamic lesions. *Mult Scler* 2020;26:177–187.
235. Jonas SN, Izbudak I, Frazier AA, Harrison DM. Longitudinal Persistence of Meningeal Enhancement on Postcontrast 7T 3D-FLAIR MRI in Multiple Sclerosis. *AJNR Am J Neuroradiol* 2018;39:1799–1805.
236. Ighani M, Jonas S, Izbudak I, et al. No association between cortical lesions and leptomeningeal enhancement on 7-Tesla MRI in multiple sclerosis. *Mult Scler* 2020;26:165–176.
237. Absinta M, Cortese ICM, Vuolo L, et al. Leptomeningeal gadolinium enhancement across the spectrum of chronic neuro-inflammatory diseases. *Neurology* 2017;88:1439–1444.
238. Absinta M, Vuolo L, Rao A, et al. Gadolinium-based MRI characterization of leptomeningeal inflammation in multiple sclerosis. *Neurology* 2015;85:18–28.
239. Asgari N, Flanagan EP, Fujihara K, et al. Disruption of the leptomeningeal blood barrier in neuromyelitis optica spectrum disorder. *Neurol Neuroimmunol Neuroinflammation* 2017;4:e343.
240. Tzanetakos D, Tzartos JS, Vakraou AG, et al. Cortical involvement and leptomeningeal inflammation in myelin oligodendrocyte glycoprotein antibody disease: A three-dimensional fluid-attenuated inversion recovery MRI study. *Mult Scler* 2022;28:718–729.
241. Wu CH, Lirng JF, Ling YH, et al. Noninvasive characterization of human lymphatics and meningeal lymphatics in an in vivo model of blood-brain barrier leakage. *Ann Neurol* 2021;89:111–124.
242. Nylund M, Sucksdorff M, Matilainen M, et al. Phenotyping of multiple sclerosis lesions according to innate immune cell activation using 18 kDa translocator protein-PET. *Brain Commun* 2021;4:fcab301.
243. Sucksdorff M, Matilainen M, Tuisku J, et al. Brain TSPO-PET predicts later disease progression independent of relapses in multiple sclerosis. *Brain* 2020;143:3318–3330.
244. Herranz E, Gianni C, Louapre C, et al. Neuroinflammatory component of gray matter pathology in multiple sclerosis. *Ann Neurol* 2016;80:776–790.
245. Herranz E, Louapre C, Treaba CA, et al. Profiles of cortical inflammation in multiple sclerosis by 11C-PBR28 MR-PET and 7 Tesla imaging. *Mult Scler* 2020;26:1497–1509.
246. Datta G, Colasanti A, Kalk N, et al. 11C-PBR28 and 18F-PBR111 Detect White Matter Inflammatory Heterogeneity in Multiple Sclerosis. *J Nucl Med* 2017;58:1477–1482.
247. Datta G, Colasanti A, Rabiner EA, et al. Neuroinflammation and its relationship to changes in brain volume and white matter lesions in multiple sclerosis. *Brain* 2017;140:2927–2938.
248. Rissanen E, Tuisku J, Rokka J, et al. In vivo detection of diffuse inflammation in secondary progressive multiple sclerosis using PET imaging and the Radioligand ¹¹C-PK11195. *J Nucl Med* 2014;55:939–944.
249. Rissanen E, Tuisku J, Vahlberg T, et al. Microglial activation, white matter tract damage, and disability in MS. *Neurol Neuroimmunol Neuroinflamm* 2018;5:e443.
250. Hamzaoui M, Garcia J, Boffa G, et al. Positron Emission Tomography with [18 F]-DPA-714 Unveils a Smoldering Component in Most Multiple Sclerosis Lesions which Drives Disease Progression. *Ann Neurol* 2023;94:366–383.
251. Politis M, Giannetti P, Su P, et al. Increased PK11195 PET binding in the cortex of patients with MS correlates with disability. *Neurology* 2012;79:523–530.
252. Colasanti A, Guo Q, Muhler N, et al. In vivo assessment of brain white matter inflammation in multiple sclerosis with (18F)-PBR111 PET. *J Nucl Med* 2014;55:1112–1118.
253. Toscano S, Oteri V, Chisari CG, et al. Cerebrospinal fluid neurofilament light chains predicts early disease-activity in Multiple Sclerosis. *Mult Scler Relat Disord* 2023;80:105131.
254. Disanto G, Barro C, Benkert P, et al. Serum Neurofilament light: A biomarker of neuronal damage in multiple sclerosis. *Ann Neurol* 2017;81:857–870.
255. Lie IA, Kaçar S, Wesnes K, et al. Serum neurofilament as a predictor of 10-year grey matter atrophy and clinical disability in multiple sclerosis: a longitudinal study. *J Neurol Neurosurg Psychiatry* 2022;93:849–857.
256. Manouchehrinia A, Stridh P, Khademi M, et al. Plasma neurofilament light levels are associated with risk of disability in multiple sclerosis. *Neurology* 2020;94:e2457–e2467.
257. Abdelhak A, Benkert P, Schaedelin S, et al. Neurofilament light chain elevation and disability progression in multiple sclerosis. *JAMA Neurol* 2023;80:1317.
258. Rosenstein I, Axelsson M, Novakova L, et al. Intrathecal kappa free light chain synthesis is associated with worse prognosis in relapsing–remitting multiple sclerosis. *J Neurol* 2023;270:4800–4811.
259. Högel H, Rissanen E, Barro C, et al. Serum glial fibrillary acidic protein correlates with multiple sclerosis disease severity. *Mult Scler J* 2020;26:210–219.
260. Abdelhak A, Foschi M, Abu-Rumeileh S, et al. Blood GFAP as an emerging biomarker in brain and spinal cord disorders. *Nat Rev Neurol* 2022;18:158–172.
261. Meier S, Willems EAJ, Schaedelin S, et al. Serum glial fibrillary acidic protein compared with neurofilament light chain as a biomarker for disease progression in multiple sclerosis. *JAMA Neurol* 2023;80:287–297.
262. Masvekar R, Phillips J, Komori M, et al. Cerebrospinal fluid biomarkers of myeloid and glial cell activation are correlated with multiple sclerosis lesional inflammatory activity. *Front Neurosci* 2021;15:649876.
263. Comabella M, Deutschmann C, Midaglia L, et al. Chitinase 3-like 1 is not a target antigen in patients with multiple sclerosis. *Mult Scler J* 2021;27:1455–1457.
264. Sand IK, Krieger S, Farrell C, Miller AE. Diagnostic uncertainty during the transition to secondary progressive multiple sclerosis. *Mult Scler J* 2014;20:1654–1657.
265. Iaffaldano P, Portaccio E, Lucisano G, et al. Multiple sclerosis progression and relapse activity in children. *JAMA Neurol* 2023;81:50–58.

266. Benkert P, Meier S, Schaedelin S, et al. Serum neurofilament light chain for individual prognostication of disease activity in people with multiple sclerosis: a retrospective modelling and validation study. *Lancet Neurol* 2022;21:246–257.
267. Marastoni D, Pisani AI, Schiavi G, et al. CSF TNF and osteopontin levels correlate with the response to dimethyl fumarate in early multiple sclerosis. *Ther Adv Neurol Disord* 2022;15:17562864221092124.
268. Marastoni D, Magliozzi R, Bolzan A, et al. CSF Levels of CXCL12 and Osteopontin as Early Markers of Primary Progressive Multiple Sclerosis. *Neurol Neuroimmunol Neuroinflamm* 2021;8:e1083.